

Isthmic spondylolisthesis during aromatase inhibitor treatment in a pre-pubertal boy with congenital adrenal hyperplasia

Jaimes N¹, Clemente M¹, Fontecha G², Campos A¹, Yeste D¹.

¹Department of Paediatric endocrinology Hospital Maternal-Infantil Vall d'Hebron, Barcelona, Spain

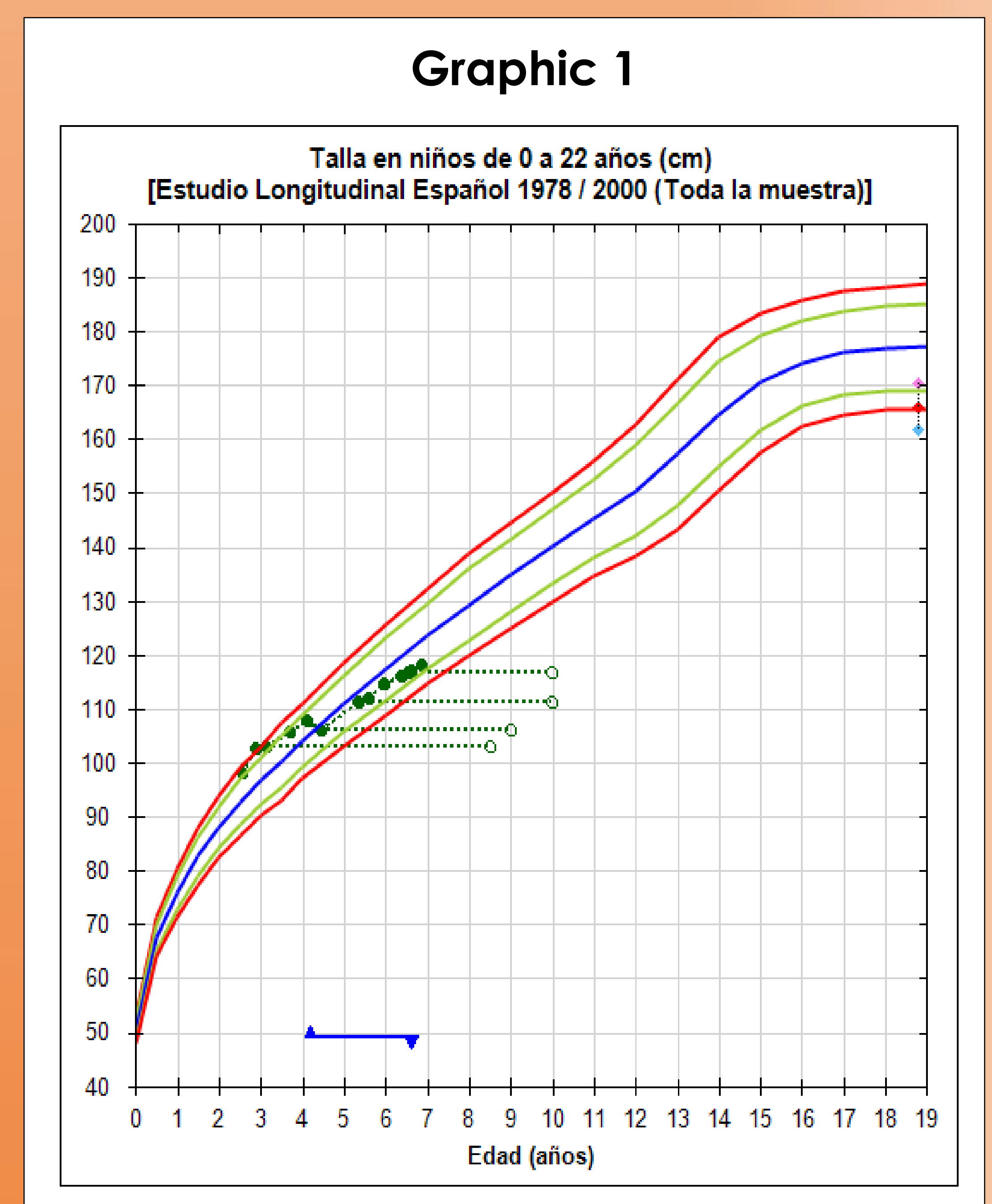
² Department of orthopaedics Hospital Vall d'Hebron, Barcelona, Spain

INTRODUCTION

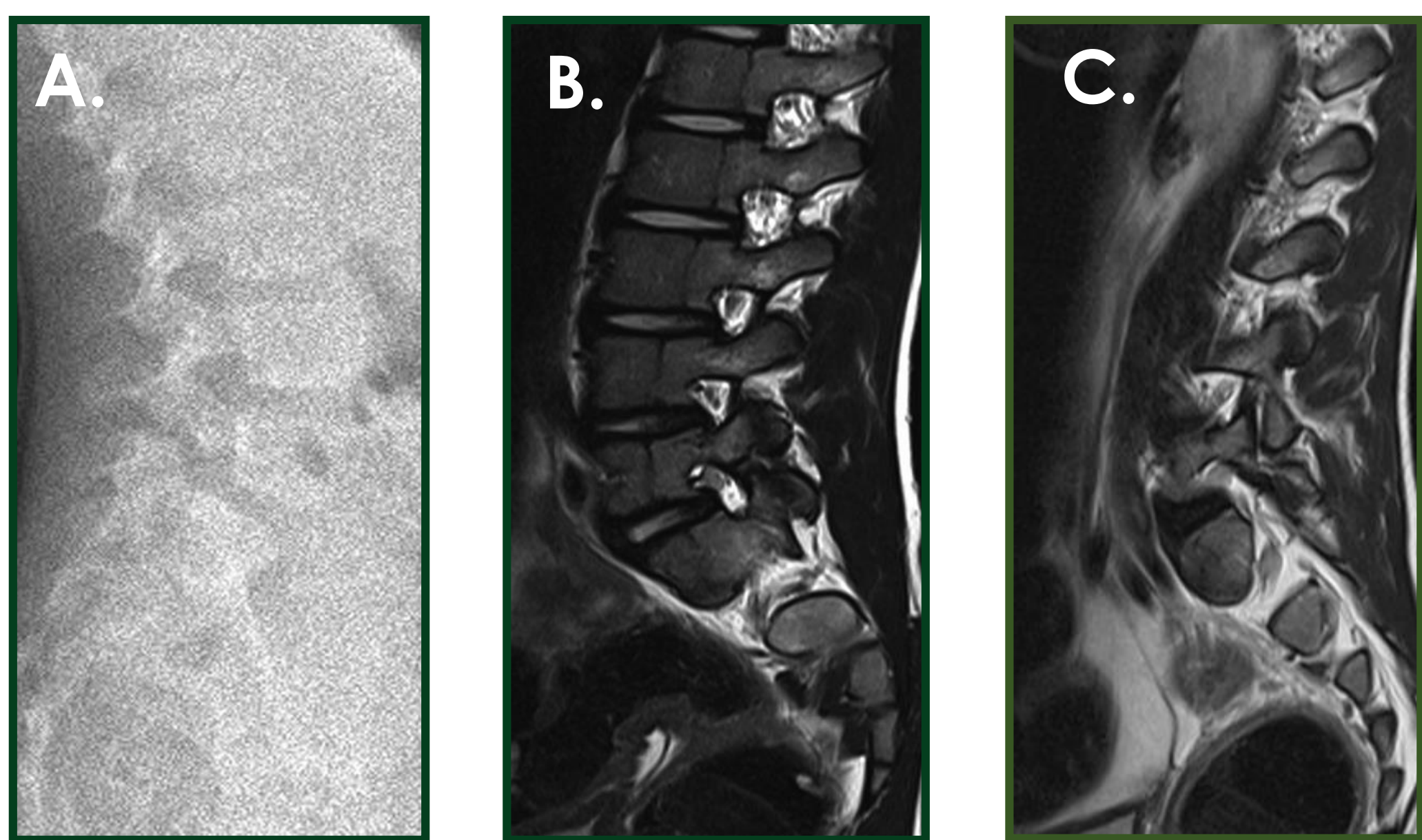
Treatment in some patients with the classical form of congenital adrenal hyperplasia (CAH) is difficult since they need high doses of glucocorticoids to suppress excess adrenal androgen secretion, which consequent slowing of growth velocity and poor predicted adult height. In this selected case AI was used, with the aim of reducing glucocorticoid doses without hyperandrogenism exerting a negative effect on bone maturation.

CASE REPORT

- A 6-year-old boy with simple virilising CAH was diagnosed at 2 years and 7 months of age because of pubic hair and accelerated growth velocity (bone age 8 years). (Graphic 1)
- Personal history: 39 weeks, birth weight 3690 grams, length 51 cm.
- Genetic study: CYP21A: compound heterozygosity Prol30Leu/Intr2.
- He needed high doses of hydrocortisone, 20mg/m²bs/ per day, with subsequent decline in growth velocity. (1.2cm/ per year - 6.2 SD).
- At four years of age: it was decided to add fludrocortisone, optimise the dosage and frequency of hydrocortisone administration every 6 hours, and anastrozole was started at doses of 1mg per day.
- Developmental control: bone mineral density by DXA, lumbar X-ray and lipid levels before and during treatment.
- At six years, 4 months of age and after two years of anastrozole treatment, control lumbar X-ray showed: isthmic spondylolisthesis L5-S1. Diagnosis of spondylolisthesis was made. The patient is currently symptom-free.
- During anastrozole treatment, the patient showed an improvement in growth velocity, hydrocortisone doses were reduced to 14.6mg/ m² bs per day and bone age progression slowed. (Table 1)
- DXA: Before: 0.657g/cm². End of treatment: 0.678 g/cm² (Z score +0.5 SDS)



COMPLEMENTARY EXAMINATIONS



- **Figure A.** lateral X-ray showing 33% anterior spondylolisthesis L5-S1 with lordosis of 22°
- **Figure B.** lumbar MRI T1 showing the isthmic defect on the left side
- **Figure C.** lumbar MRI T1 showing the isthmic defect on the right side

Table 1

Age (Years)	17 OHP (ng/ml)	Testosterone (ng/dl)	Hydrocortisone (mg/m ² bs/per day)
2.7	>51	64.2	15
3	6.71	<20	20
3.7	8.41	16.1	17.1
4	1.30	17.8	18
4.5	6.0	12.93	16.4
6.4	15.9	26.2	14.6

CONCLUSION

The use of AI is a therapeutic option to consider in some selected cases of the classical form of CAH requiring high doses of glucocorticoids. However, the use of anastrozole therapy, particularly in prepuberty or early puberty, may predispose to vertebral changes. We recommend serial evaluation of vertebral morphology.

DISCUSSION

Spondylolisthesis is weird at the age of 6 years since his height and weight were insufficient to cause mechanical stress. These findings led us to consider the pathological role of anastrozole.

- Shulman D, Francis G, Palmert M: Use of Aromatase inhibitors in children and adolescents with disorders of growth and adolescent development. Paediatrics 2008; 121
- Geffner ME: Aromatase inhibitors to augment height: continued caution and study required. J Clin Res Pediatr Endocrinol 2009;1(6):256-61

