

Allopurinol Ameliorates Non-alcoholic Fatty Liver Disease in Rats

Hüseyin Anıl Korkmaz, Hüseyin Aktug, Dinçer Atila, Vatan Barışık ,Nur Arslan, Oytun Erbaş

Introduction

Xanthine oxidase, which causes oxidative stress in several pathological states such as ischemia reperfusion injury and acute liver damage induced by alcohol, is an important determinant of the oxidation in diabetes and alcohol-induced liver injury . Allopurinol, a xanthine oxidase inhibitor, has been shown to exert protective effects on early alcohol-induced liver disease. The aim of this study was to evaluate whether allopurinol affects the course of experimental non-alcoholic fatty liver disease in rats.

Materials and Methods

Twenty one mature, albino Sprague Dawley rats were divided into three groups: controls (n = 7, normal diet for 12 weeks); NAFLD rat models (by feeding water containing 30% fructose for first 8 weeks) treated with allopurinol for last 4 weeks (n = 7) and treated with placebo, saline for last 4 weeks (n = 7). Afterwards, all rats were anesthetized with an i.p. of ketamine (40 mg/kg)/xylazine (4 mg/kg), and a hepatectomy performed as a histopathological examination (25). Liver pathology was determined according to steatosis (the percentage of liver cells containing fat): <25% = 1+, 25% - 50% = 2+, 51% - 75% = 3+, >75% = 4+; inflammation and necrosis: 1 focus per low-power field = 1+; and 2 or more foci= 2+ . Pathology was blind scored by one study author and an outside expert in rat liver pathology.

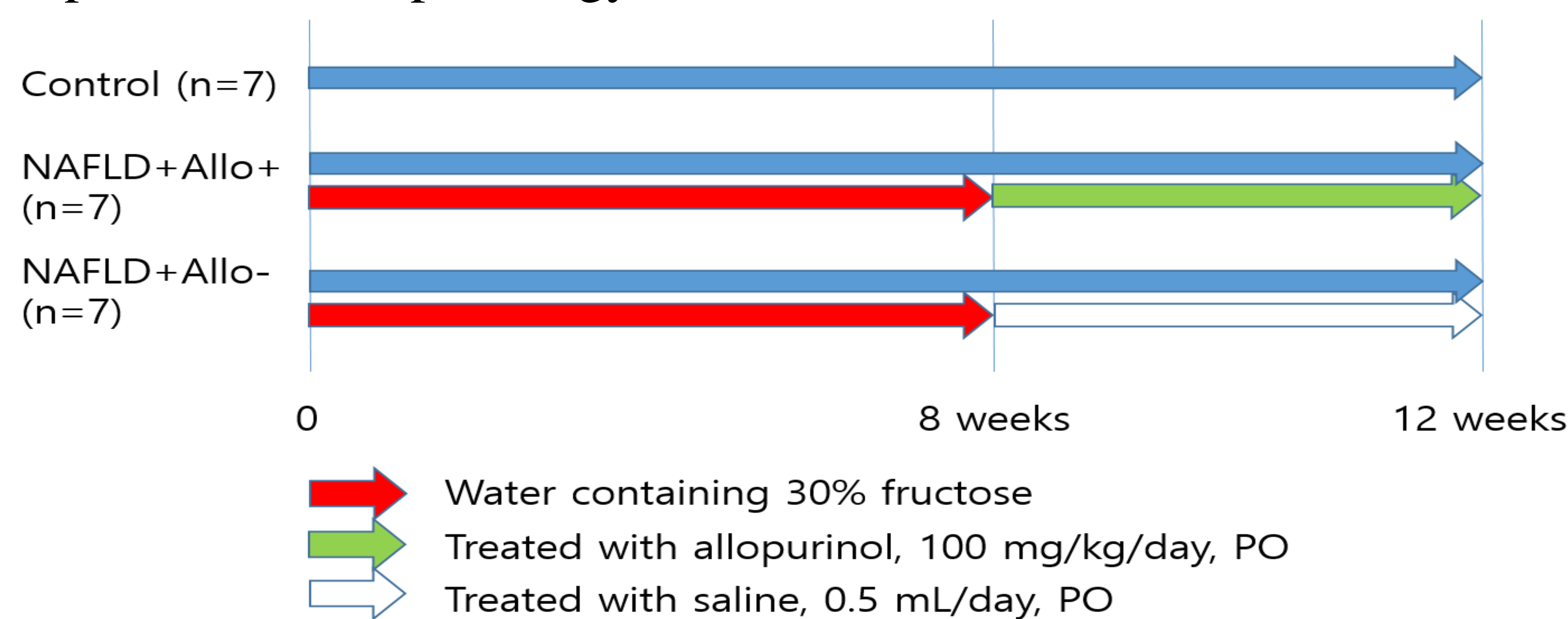


Figure 1: The experimental design into a diagram

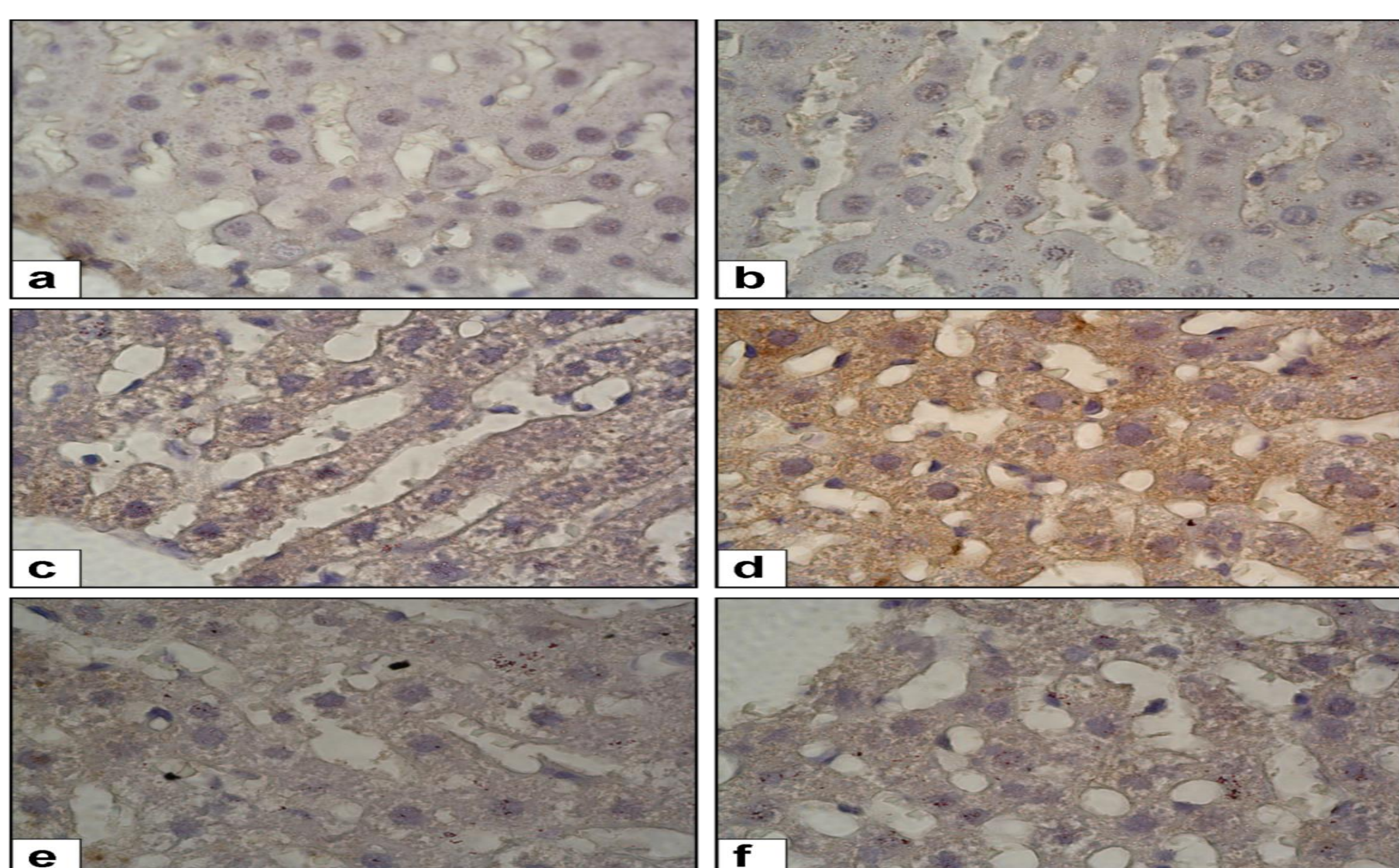


Figure 2: Interleukin 1 (IL-1) and 2 (IL-2) expressions of livers in untreated group, Allopurinol group and Non-allopurinol group

Results

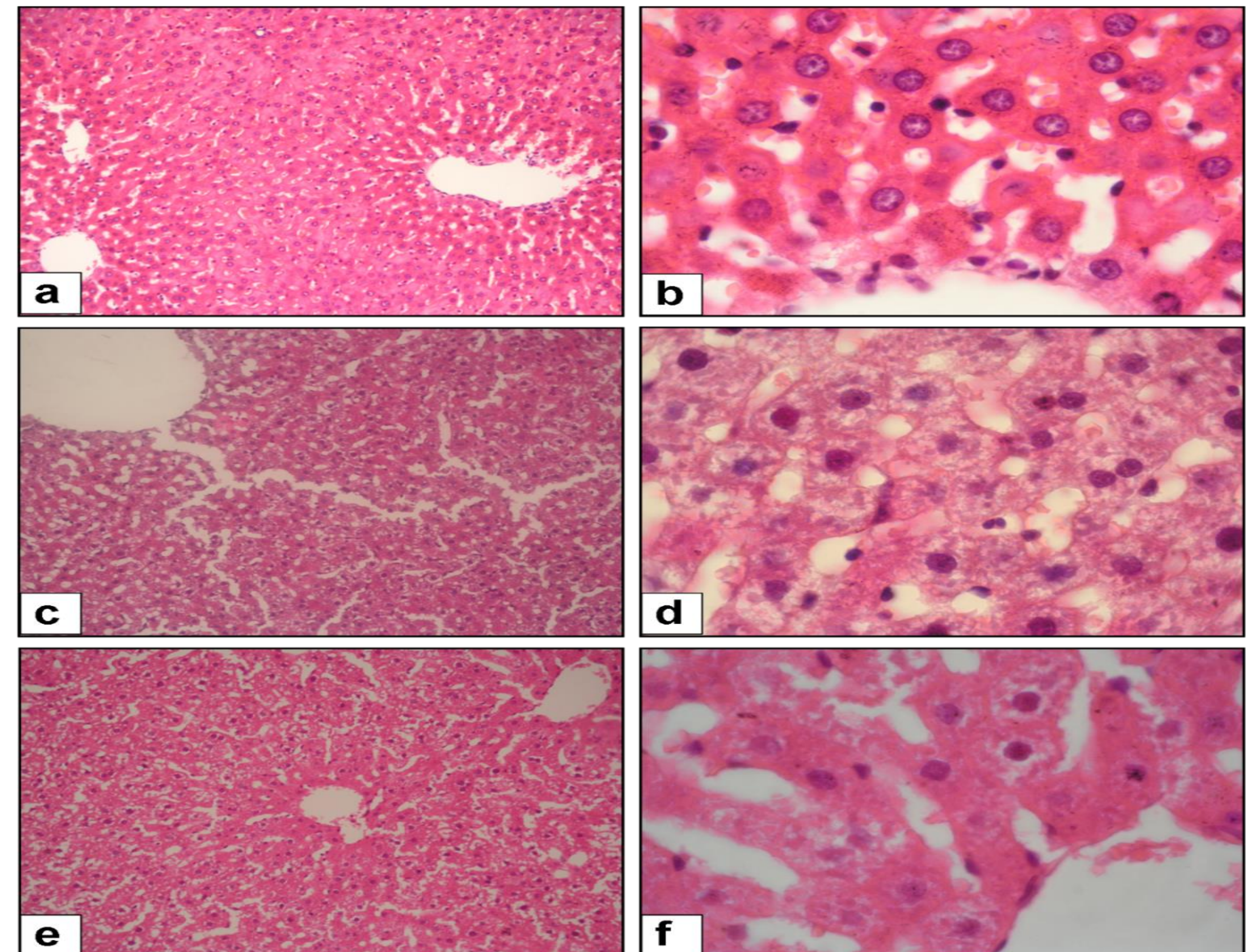


Figure 3: Histopathological representation of the liver by hematoxylin and eosin staining

In the untreated group, no signs of steatosis or inflammatory infiltrate were observed in the liver tissues. However, severe fat accumulation and mild inflammation were detected in the experimental group. Non-allopurinol group had significantly higher mean liver histopathological score than the untreated group (5.45 ± 0.24 vs. 1.06 ± 0.18 , respectively, $p=0.0004$). Allopurinol group had lower mean liver histopathological score than non-allopurinol group (2.13 ± 0.35 vs. 5.45 ± 0.24 , respectively, $p=0.003$). IL-1 and IL-2 immunorexpression significantly increased in non-allopurinol group compared to the untreated group (IL-1: 12.85 ± 3.26 vs. 4.12 ± 0.17 , respectively, $p=0.012$, IL-2: 56.23 ± 7.12 vs. 5.78 ± 0.19 , respectively, $p=0.001$). Allopurinol group had significantly lower IL-1 and IL-2 immunorexpression than non-allopurinol group (IL-1: 5.76 ± 0.43 vs. 12.85 ± 3.26 , respectively, $p=0.023$, IL-2: 8.55 ± 1.14 vs. 56.23 ± 7.12 , respectively, $p=0.002$). There were no statistical differences between the allopurinol and the untreated group in terms of liver histopathological score, IL-1 and IL-2 immunorexpression (2.13 ± 0.35 vs. 1.06 ± 0.18 , $p=0.12$, IL-1: 5.76 ± 0.43 vs. 4.12 ± 0.17 , $p=0.24$, IL-2: 8.55 ± 1.14 vs. 5.78 ± 0.19 , $p=0.08$).

Conclusion

This study showed that allopurinol ameliorates NAFLD, most likely by inhibition of xanthine oxidase and scavenger of oxidants.

