

Pharmacotherapy and the effects on LDL levels and growth in 2 children with severe Familial Hypercholesterolemia

Aravind Venkatesh S¹, Fabian Yap¹

Department of Endocrinology¹, KK Women's and Children's Hospital, SINGAPORE

BACKGROUND

- Familial Hypercholesterolemia (FH) is mainly an autosomal dominant disorder characterized by high total and LDL cholesterol (LDL-C).
- There are 2 types of Familial Hypercholesterolemia, Heterozygous (HeFH), prevalence 1:200 – 250) and Homozygous (HoFH or Compound HeFH, prevalence 1:160,000 – 250,000).
- Three genes are commonly implicated in autosomal dominant FH (LDLR, Apo B, PCSK9) while the uncommon autosomal recessive form is associated with LDLRAP1 gene.
- Homozygous forms are the most severe with extremely high levels of LDL-C. Most with HoFH experience severe CAD by their mid-20's, and severe aortic stenosis is also common.
- When onset is in early childhood, higher risk of coronary heart disease warrant strict management to improve the life expectancy.
- **KNOWLEDGE GAP:** Pharmacotherapy in HeFH is well documented but less is known about the use and efficacy of various medications within individuals with severe phenotypes.

STUDY AIM:

To present the sequential changes in LDL-C levels, anthropometry and pharmacotherapy in 2 children with severe pre-pubertal onset FH treated with a single drug and/or a combination during a period of 8 years.

METHODS

- 2 pre-pubertal children with severe FH diagnosed in 2009 and 2010, high LDL-C levels at presentation (> 15.6mmol/L = 600 mg/dl) and with good compliance to diet and medications, were chosen.
- Data was retrospectively collected to look at the growth, medications used and doses at which they were used. LDL-C levels were charted over 8 years and percent reduction from peak LDL-C was determined.

Growth

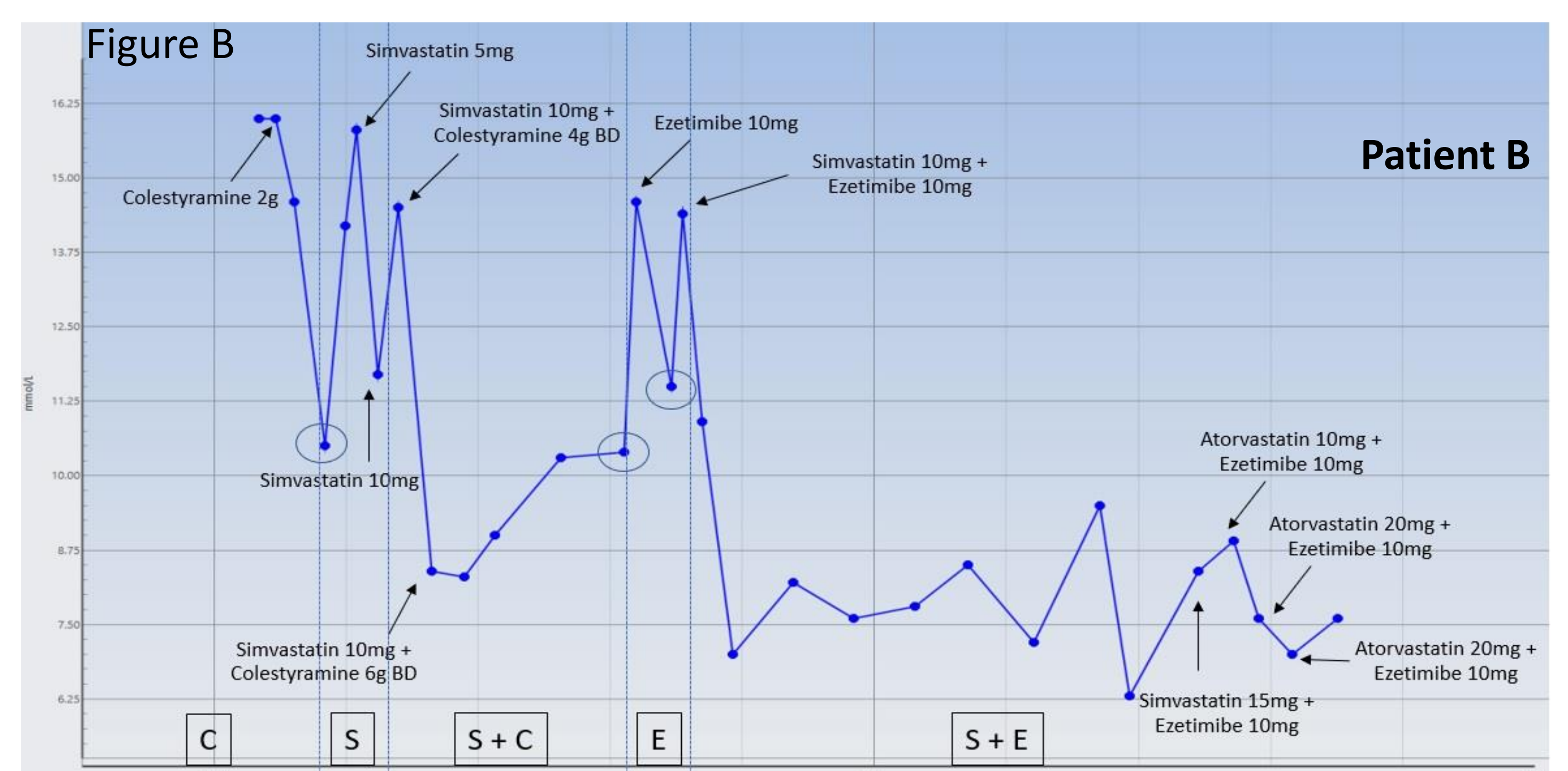
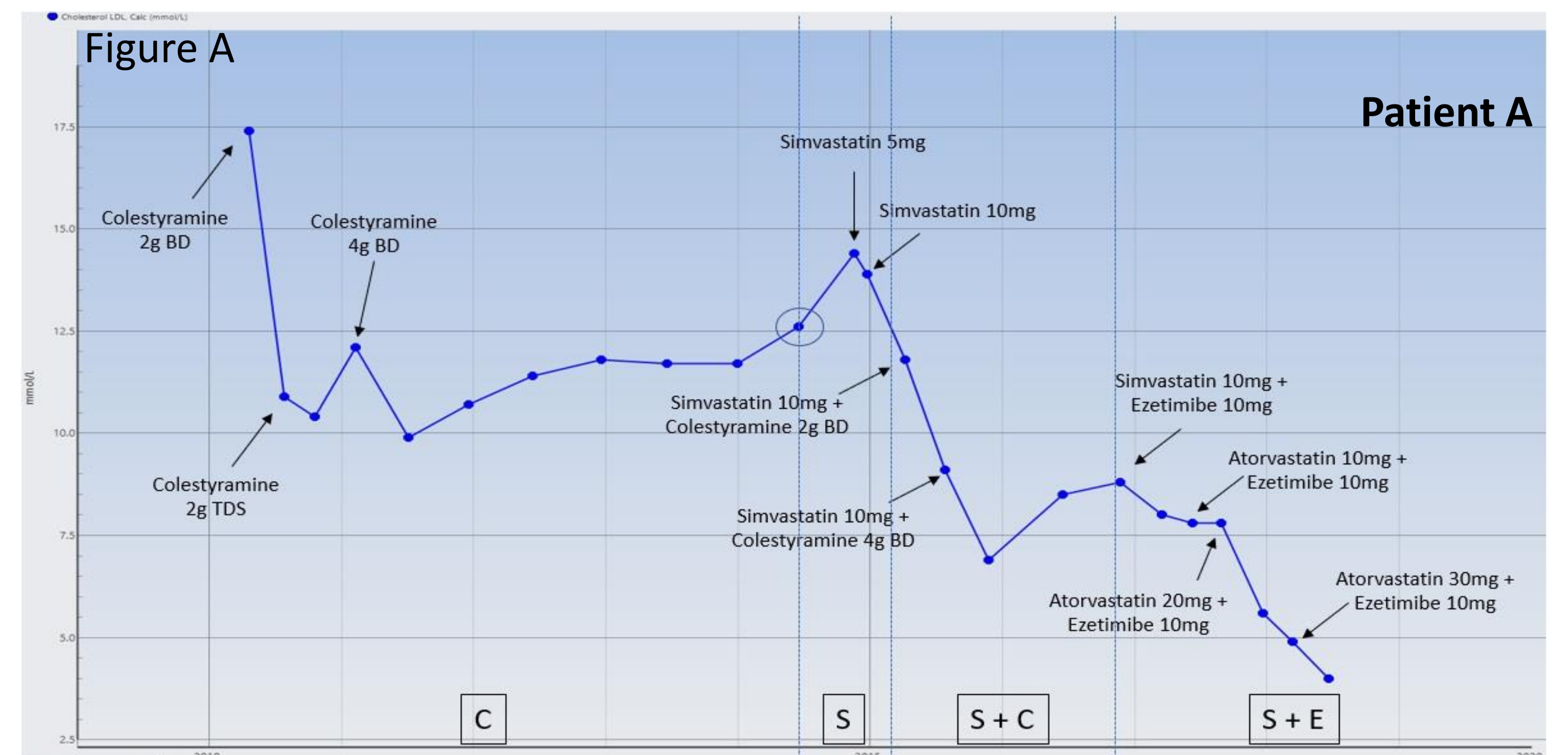
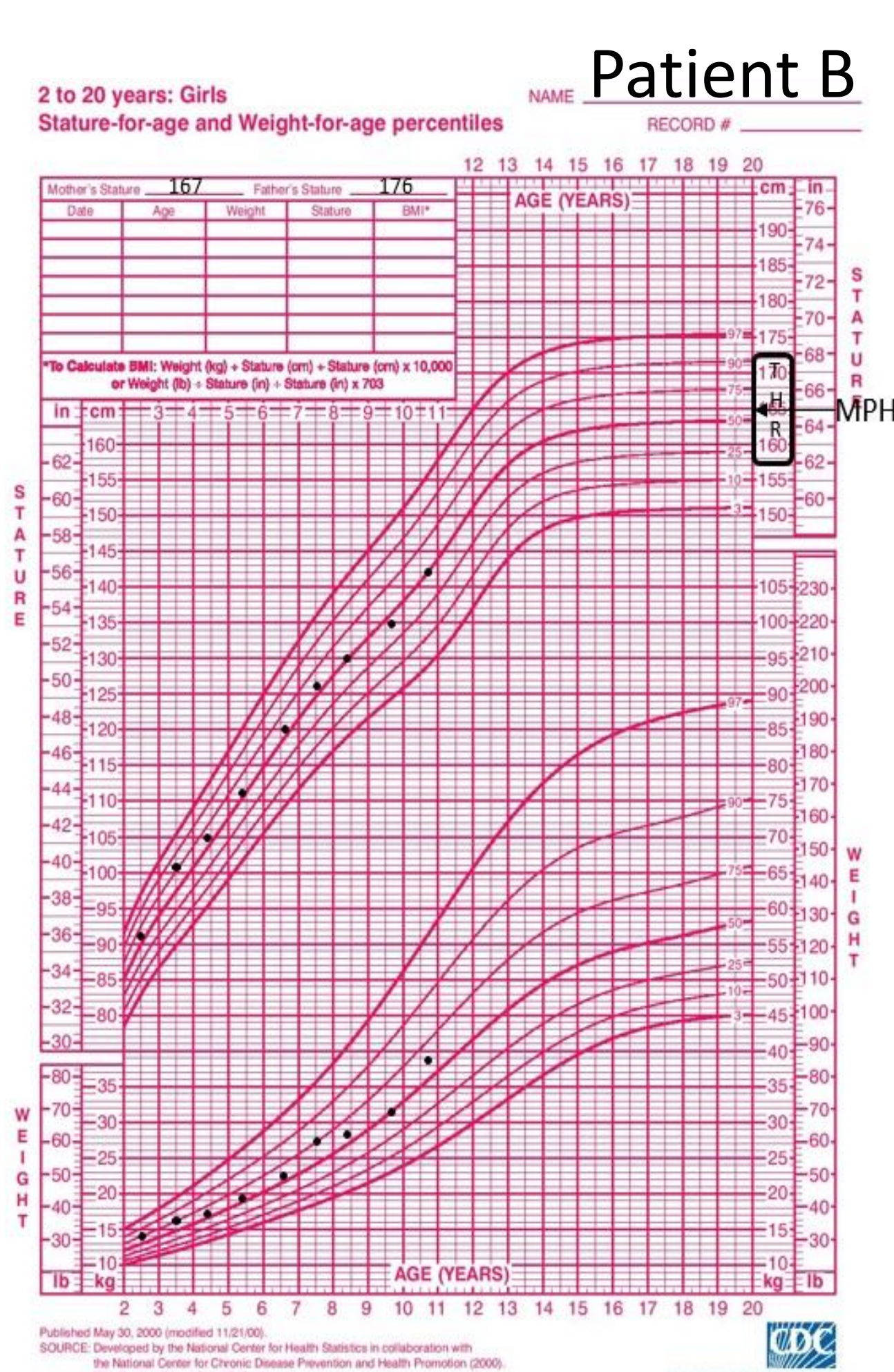
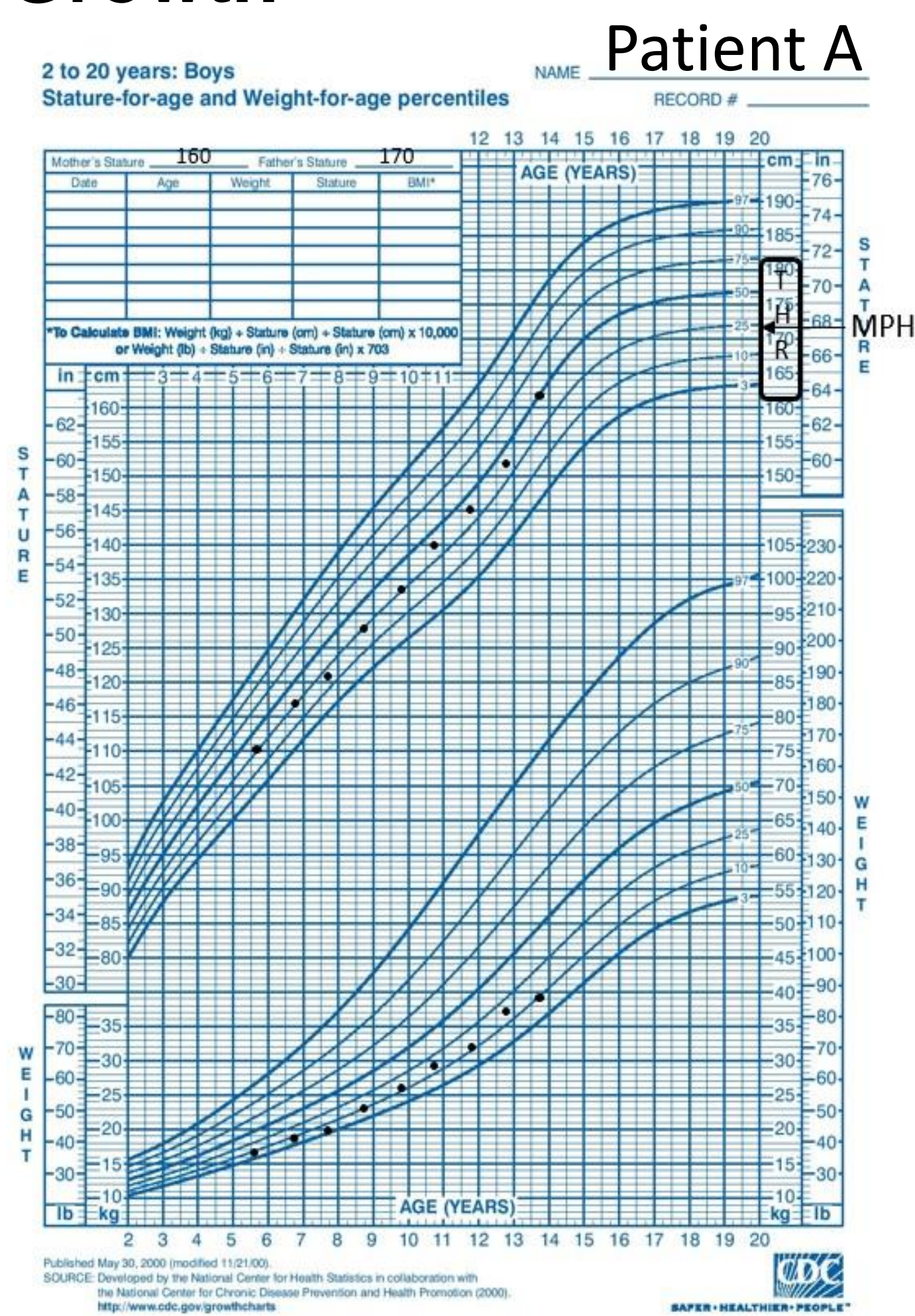


Figure A and Figure B represent (a) LDL-C changes over time for patients A and B respectively. (b) Timeline on the X axis (c) LDL-C in mmol/L on the Y axis. (d) Circled areas represent stopping of medication to allow for washout period of at least 4 weeks. (e) Different Phases, C - Colestyramine, S - Statin, E - Ezetimibe

RESULTS

- A and B presented with multiple skin lesions over the extensor aspects of both knees, ankles and elbows. Punch biopsy: xanthomas.
- Child A (5y 7m, both parents with high LDL-C) and B (2y 6m, dad with high LDL-C) had LDL-C suggestive of HoFH at 17.4mmol/L and 16.0mmol/L respectively.
- Both were initiated on Colestyramine resulting in LDL-C reductions from peak by 43.2% (9.9mmol/L) and 34.4% (10.5mmol/L) with monotherapy alone.
- Since Colestyramine monotherapy was unable to achieve further improvement, a statin was added. On combination of statin and Colestyramine, LDL-C levels fell further to 60.4% and 47.5% from peak corresponding to 6.9mmol/L and 8.4mmol/L respectively.
- When Ezetimibe was combined with statin, LDL-C levels continued to fall further to 77% and 60.7% from peak, corresponding to 4.0mmol/L and 6.3mmol/L, their lowest attained levels, respectively.
- Growth data plotted over 8 years showed that growth was not affected. Both children are doing well at school. Muscle and liver enzymes were unaffected.
- Genetic Studies recently returned as follows:
 1. A: Compound heterozygous LDL receptor mutation
 2. B: Autosomal recessive hypercholesterolemia, LDLRAP1 mutation

CONCLUSION

1. Combination therapy was able to achieve 60–77% reduction of LDL-C level from peak. Ezetimibe/statin combination was more effective than Colestyramine/statin in lowering LDL-C.
2. Monotherapy with colestyramine, statin or ezetimibe alone is unable to achieve 50% reduction in our patients.
3. Ezetimibe/statin combination treatment is a safe and effective alternate to LDL apheresis in the treatment of severe FH even in very early onset pre-pubertal children below 8 years.