

INTRODUCTION

- Osteogenesis imperfecta (OI) is a genetic disorder mostly associated in mutation in one of the two genes encoding α chains of collagen type 1 (COL1A1 and COL1A2).
- Severity of symptoms varies widely caused by increase bone fragility and low bone mass.
- Poor growth and short stature has been a recognized feature of OI.
- However, there is no direct association reported in osteogenesis imperfecta and hypopituitarism.

CASE REPORT

- A Malay boy diagnosed with osteogenesis imperfecta at 3 months old . He was referred at the age of 2.2 years old for poor growth and severe failure to thrive.
- He was stunted and wasted (Figure 1&2), had large anterior fontanelle, pectus carinatum, blue sclera, high arch palate, generalized hypotonia, shortening of the limbs, micropenis and bilateral undescended testis.
- Other systems examinations were unremarkable.

Weight-for-age BOYS

Birth to 5 years (percentiles)

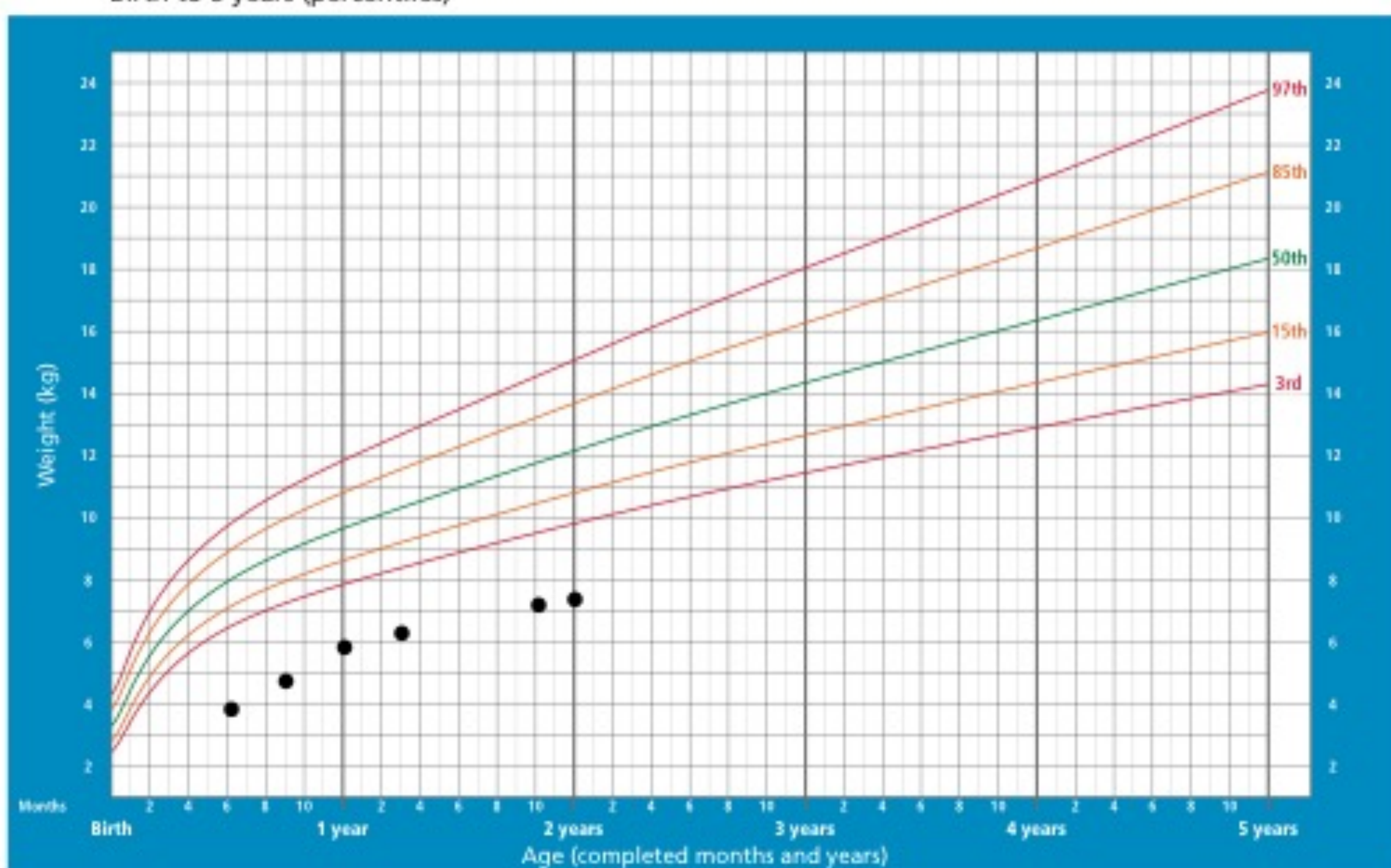


Figure 1: Serial weight throughout infancy

WHO Child Growth Standards

Length/height-for-age BOYS

Birth to 5 years (percentiles)

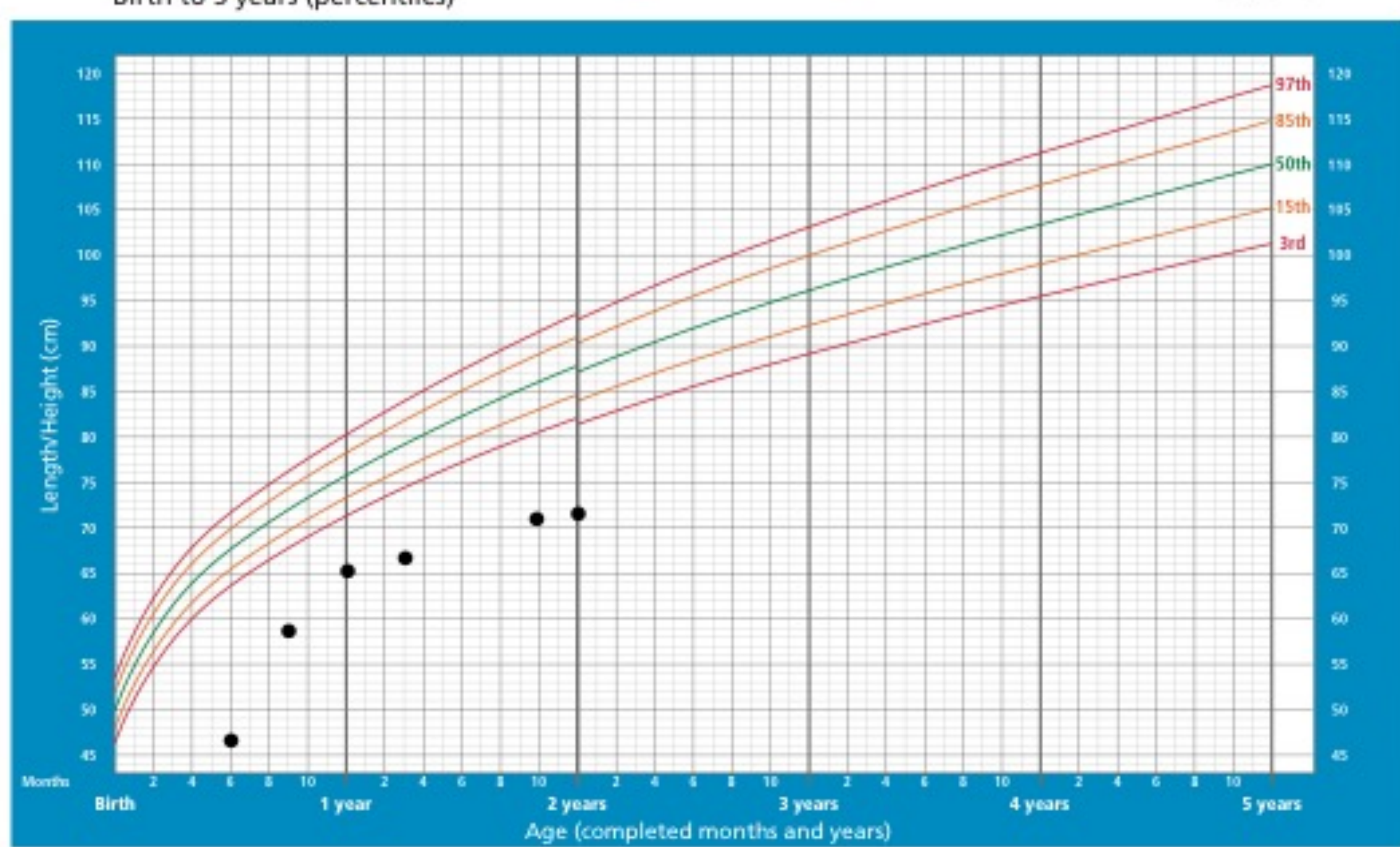


Figure 2: Serial height throughout infancy

WHO Child Growth Standards

INVESTIGATIONS AND MANAGEMENT

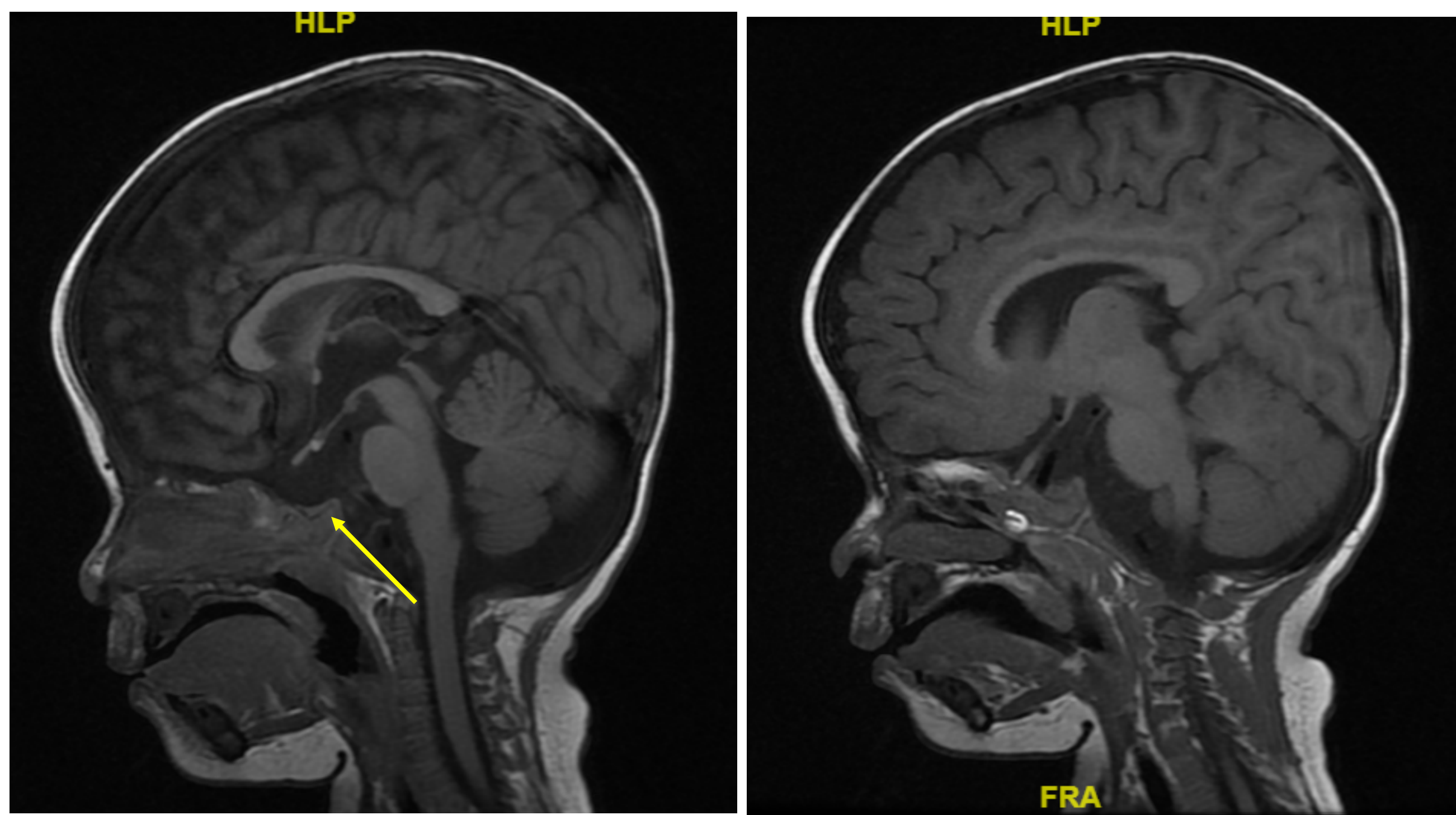
- TSH: 2.5 mU/L (0.271-7.71), fT4: 7.5 pmol/L (8.5-20.4), cortisol: 127 nmol/L (145-619), IGF-1: 8 ng/ml (15-129), ACTH: 8 pg/ml (0-46).
- Calcium: 2.6 mmol/L (2.2-2.6), PO4: 1.9 mmol/L (0.78-1.65), Mg: 0.9 mmol/L (0.53-1.11), ALP: 159 U/L (54-369), Vitamin D: 21 nmol/L (>50)
- MRI brain and pituitary (contrasted) showed small pituitary gland and hypoplastic pituitary stalk (Picture 1 &2)
- He was started on cholecalciferol, L-thyroxine and hydrocortisone replacement. Bisphosphonate therapy was continued.

DISCUSSION

- This patient had stormy neonatal period complicated by neonatal hepatitis which has resolved.
- His course of illness is complicated by multiple fractures and deformity during infancy.
- The mainstay of treatment for osteogenesis imperfecta is multidisciplinary approach including bisphosphonate therapy, rehabilitation and supportive management, depending on the severity and clinical manifestations.
- Further investigation confirms central hypothyroidism, hypocortisolism and low IGF-1 level (panhypopituitarism)
- He was planned for growth hormone therapy after optimisation of nutrition

CONCLUSION

This is the first case report to demonstrate panhypopituitarism in a child with osteogenesis imperfecta. Further genetic testing is needed to confirm mutation.



picture 1: MRI showing small pituitary gland

Picture 2: MRI showing hypoplastic pituitary stalk

REFERENCES

1. Frank Rauch, Francis H Glorieux. Osteogenesis Imperfecta. *The Lancet* 2004;363:1377-85
2. Moira S. Cheung, Francis H. Glorieux. Osteogenesis Imperfecta: Update on presentation and management. *Rev Endocr Metab Disord* 2008;9:153-60
3. G Venturi, E Tedeschi, M Mottes, M Camilot, S Viglio, F Antoniazzi, L Tato. Osteogenesis Imperfecta: clinical, biochemical and molecular findings. *Clinical Genetics* 2006;70:131-39

ACKNOWLEDGEMENT

1. Patient and parents-consent obtained for images above
2. Genetic Unit, Paediatric Department, University Malaya Medical Center