

Ovarian leydig cell tumor in an 8 years old girl misdiagnosed as congenital adrenal hyperplasia due to elevated 17-hydroxi-progesterone

Hernán García-Bruce¹, Helena Poggi M¹, Hernán García-Fernandez², Alejandro Martínez-Aguayo¹,
Mónica Arancibia^{2,3}, Paulina Baquedano⁴.

¹ Division of Pediatrics, ² School of Medicine, Pontificia Universidad Católica de Chile,

³Servicio de Pediatría Hospital Higuera, Talcahuano, Chile, ⁴ Pediatric Urology, Pontificia Universidad Católica de Chile

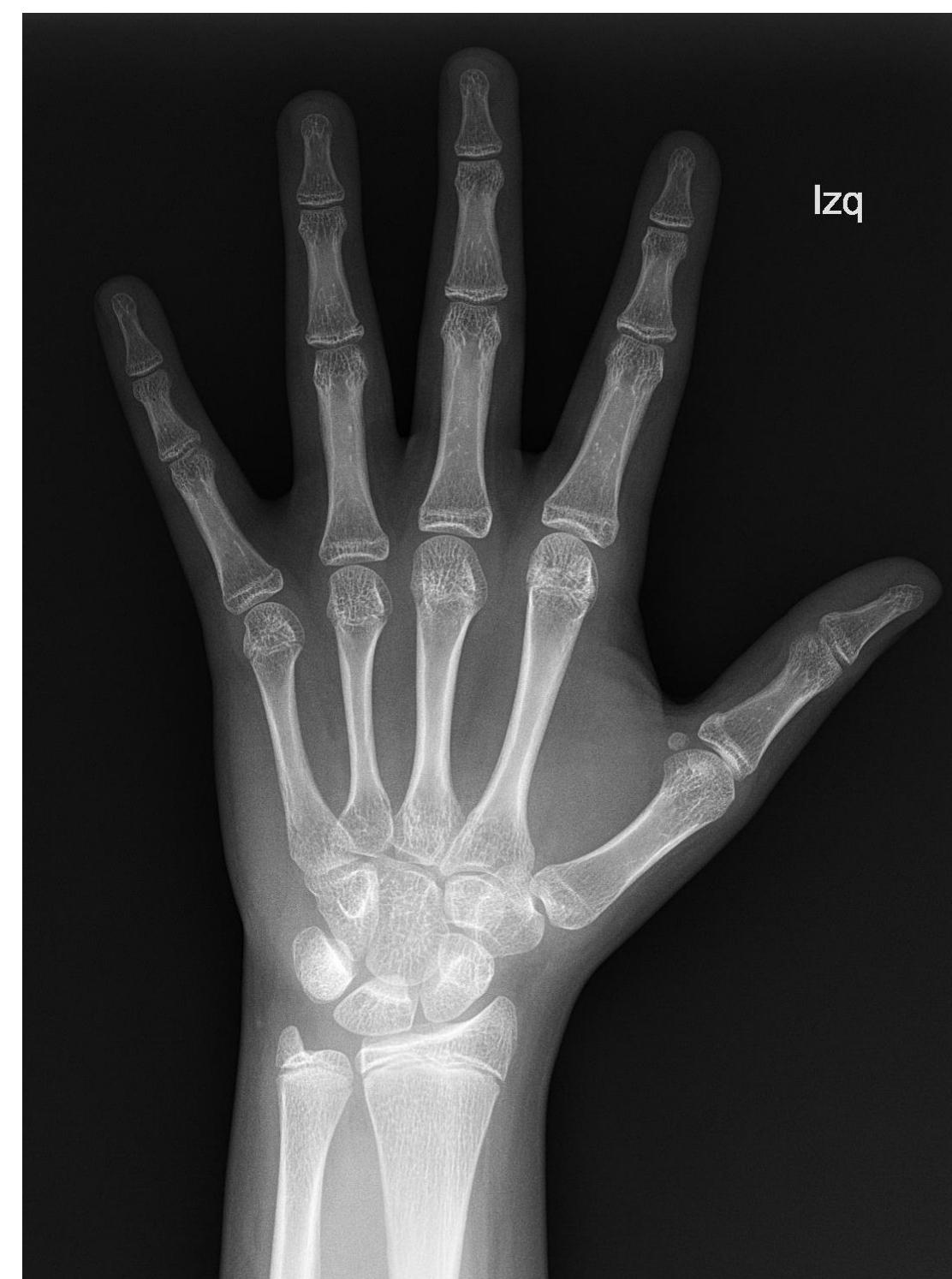Introduction

Non-classical congenital adrenal hyperplasia is the most common pathological cause of early pubarche in prepubertal patients. However, this may also be the first manifestation of central precocious puberty or an androgen producing due to an adrenal or an ovarian tumour. Objective: To present a clinical case initially misdiagnosed as Congenital Adrenal Hyperplasia that turned out to be an Ovarian Tumor of Leydig Cells

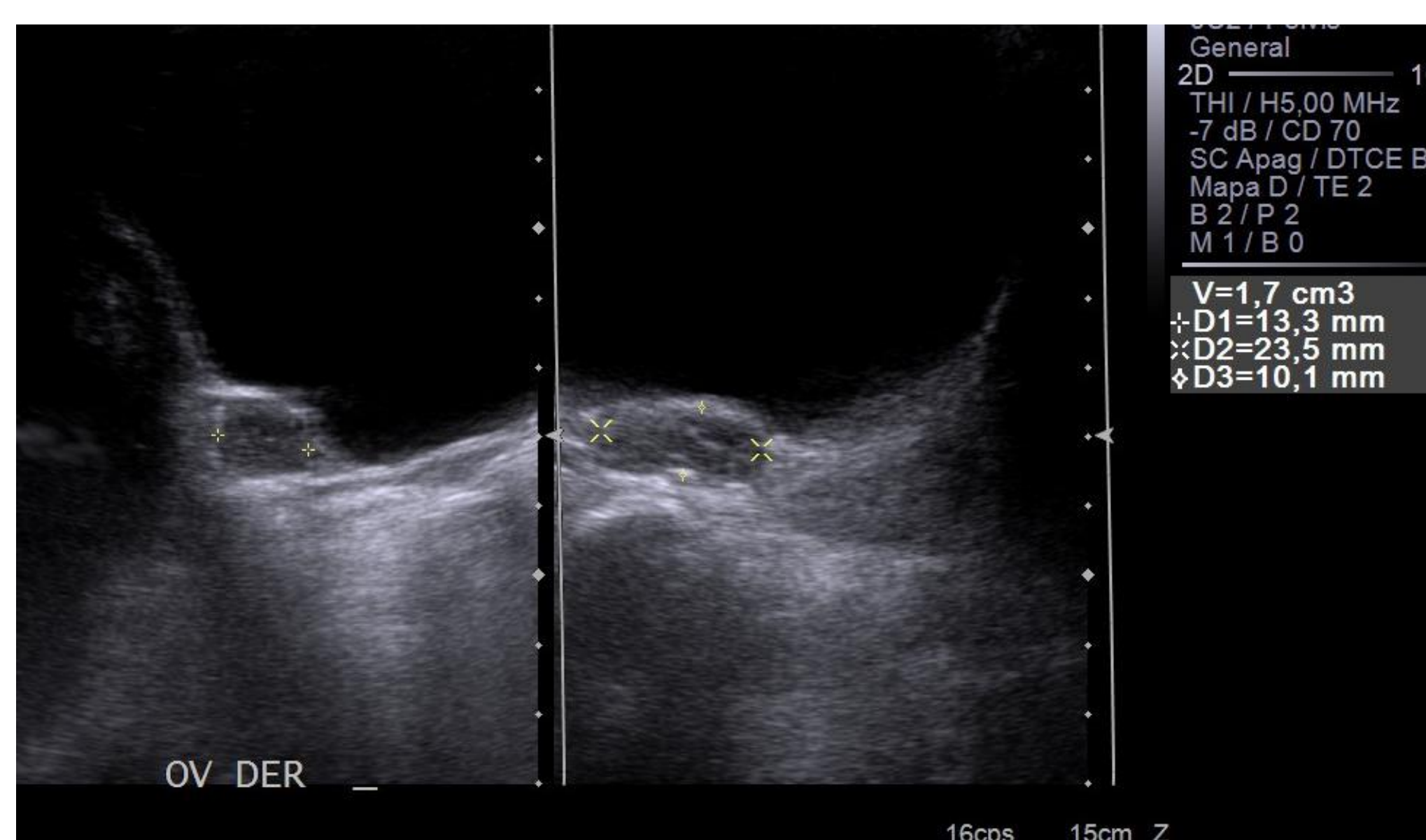
Clinical Case

An 8-year-old girl is presented with early pubarche and hirsutism, referred for further evaluation. Her height was in percentile 75 (target height: 25th percentile), her BMI in percentile 90, and blood pressure was normal. She presented hirsutism (Ferriman score 8), breast Tanner 1, pubic hair Tanner 3 and a normal clitoris.

The laboratory study showed elevated androgens levels: testosterone of 47.2 ng/dL, androstenedione of 5.1 ng/mL, basal 17-hydroxy- progesterone (17OHP) of 15 ng/dL, and normal DHEAS (0.26 ug/mL) as well as Plasma Renin Activity (0.22 ng/mL/hr).

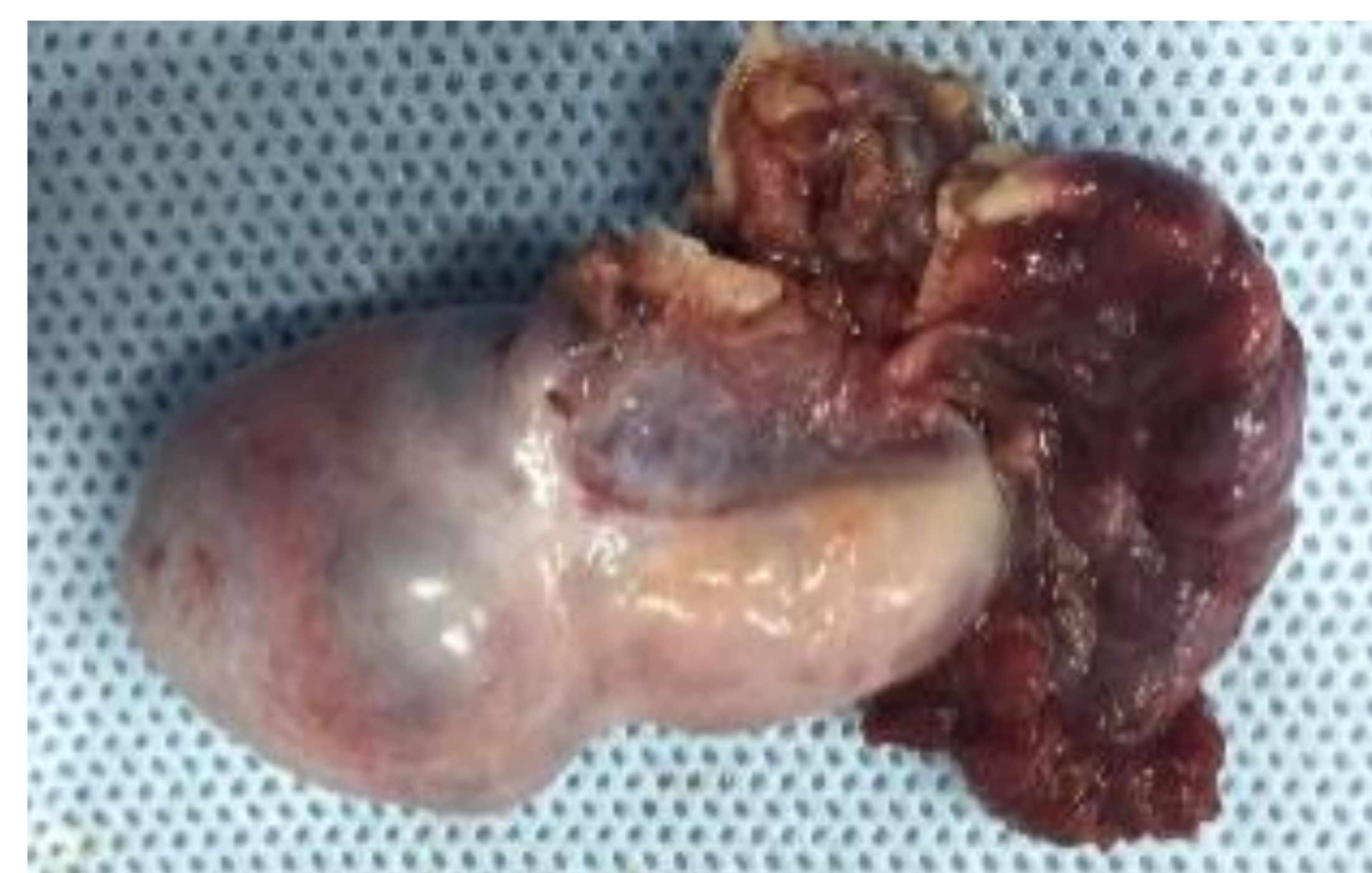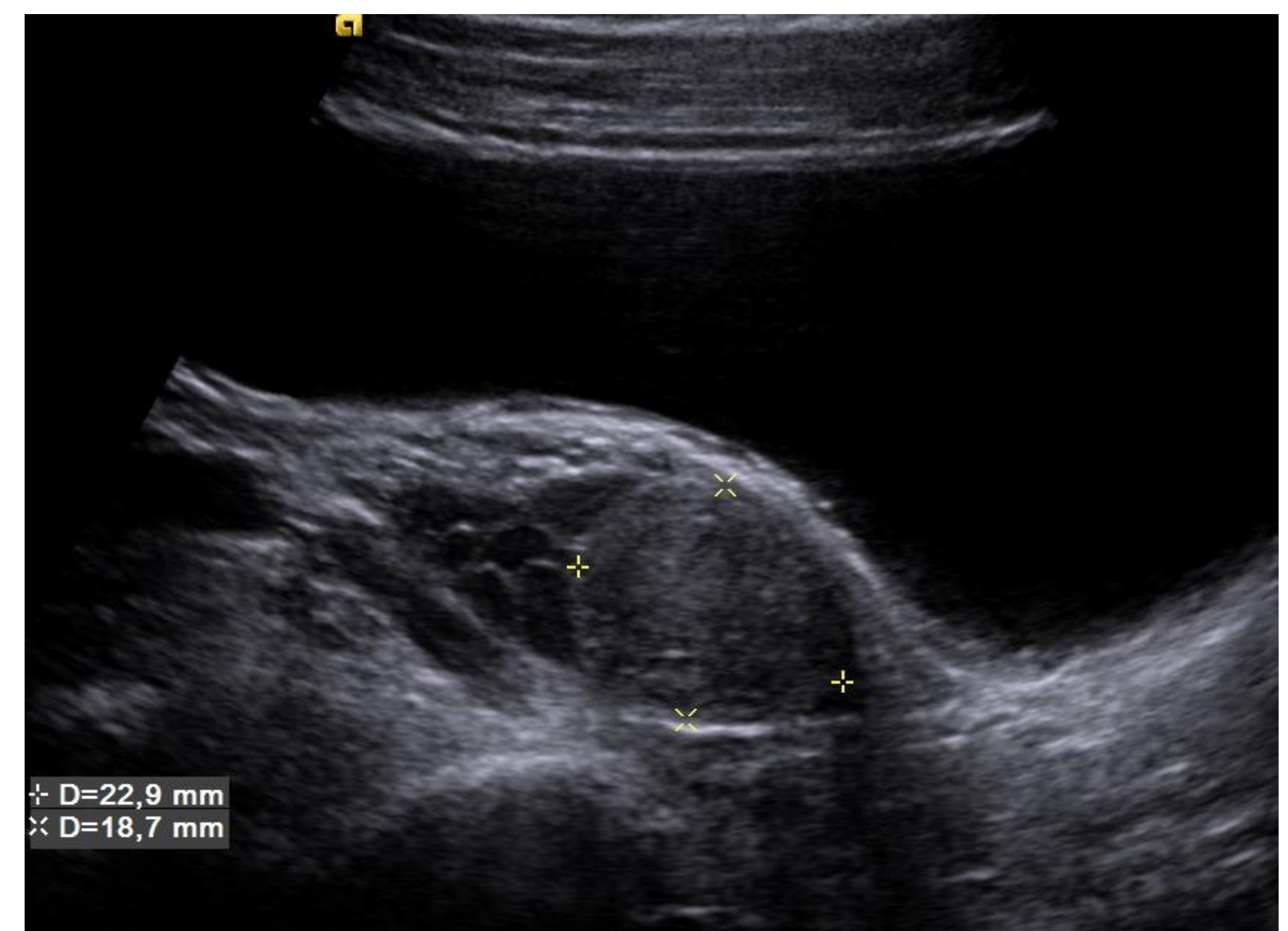


Initial imaging study showed an advanced bone age (11 years for a chronological age of 8 years four months) and a normal abdominal and pelvic ultrasonography. No pathogenic variants in the CYP21A2 gene were found. Since she could have a congenital adrenal hyperplasia another with a defect in other genes, she was treated with hydrocortisone (12 mg/m²).



Pubertal development started at 8.7 years; then analogues of LHRH were initiated. Despite both treatments, signs of virilisation accentuated progressively along with the elevation of androgens (testosterone as high as 120 ng/mL). Although different therapeutic schemes with hydrocortisone, prednisone and dexamethasone were tried, it was not possible to reduce testosterone levels.

The abdomen and pelvis MRI was performed, showing a solid nodular image of 2.1x1.6 cm in the right ovary. Biopsy analysis after laparoscopic oophorectomy demonstrated a Leydig cell tumour. One month after surgery, the patient normalised all androgenic levels, and gradual suspension of corticosteroids was started.



Conclusion

- In the presence of early pubarche, hirsutism and high 17OHP levels, Non-Classical Congenital Adrenal Hyperplasia should be suspected. However, when no pathogenic variants in the CYP21A2 gene are present, and it is associated with progressive clinical and biochemical hyperandrogenism despite adequate treatment, MRI should be performed to rule out androgen-producing tumours.