

Latest progress in tissue engineered urethral regeneration. From rabbit to dog, a step from human clinical trial for surgical treatment of VSD (Variation of Sex Development).

K Pinnagoda^{1,2*}, G Vythilingam^{1,3*}, E Vardar^{1,2}, EM Engelhardt¹, S Sothilingam³, CR Thambidorai³, T Kamarul⁴, N Hayah⁵, CH Meng⁵, M Hiew⁵, R Radzi⁵, JA Hubbell^{1,6}, P Frey¹, HM Larsson^{1,2}

1 Institute of Bioengineering, École Polytechnique Fédérale de Lausanne, CH. 2 Department of Pediatrics, Centre Hospitalier Universitaire Vaudois (CHUV), Lausanne, CH. 3 Department of Surgery, University Malaya, Kuala Lumpur, ML. 4 Department of Orthopedic, University Malaya Kuala Lumpur, ML. 5 Faculty of Veterinary Medicine, University Putra Malaysia, Serdang, ML. 6 Institute for Molecular Engineering, University of Chicago, Chicago, IL, USA.

Introduction

An acellular bovine collagen based graft with good regenerative potential already tested successfully in the rabbit model was implanted in 9 dogs. Functional and regenerative capacities are evaluated at different time points.

Methods:

Four versions of urethral grafts improved over a period of 3 years resulted in the engineering of a final acellular bovine collagen graft with enhanced mechanical property, allowing better surgical and regenerative performance. This was achieved, by varying the collagen density and fibre distribution. Our previous study in rabbits showed regeneration in a 2 cm long acellular graft. In the present study, 4cm tubular urethral grafts were implanted in 9 weight matched stray dogs. An endoscopic examination of the urethra and a contrast voiding cysto-urethrography was done at the time of euthanasia.




Fig.1: Variable densities in bovine collagen tubular scaffolds

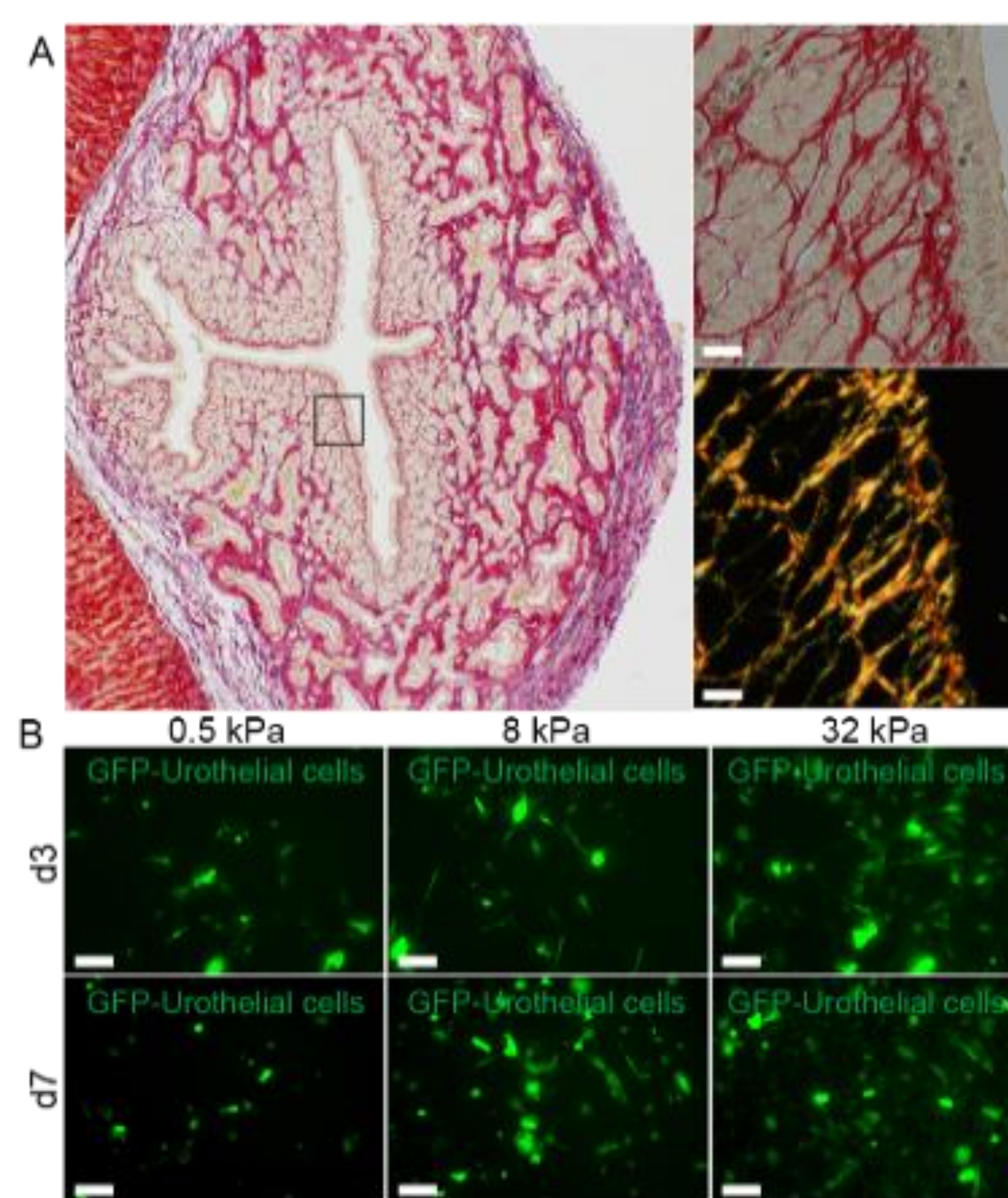


Fig.2: Better migration of urothelial cells in high density tubes

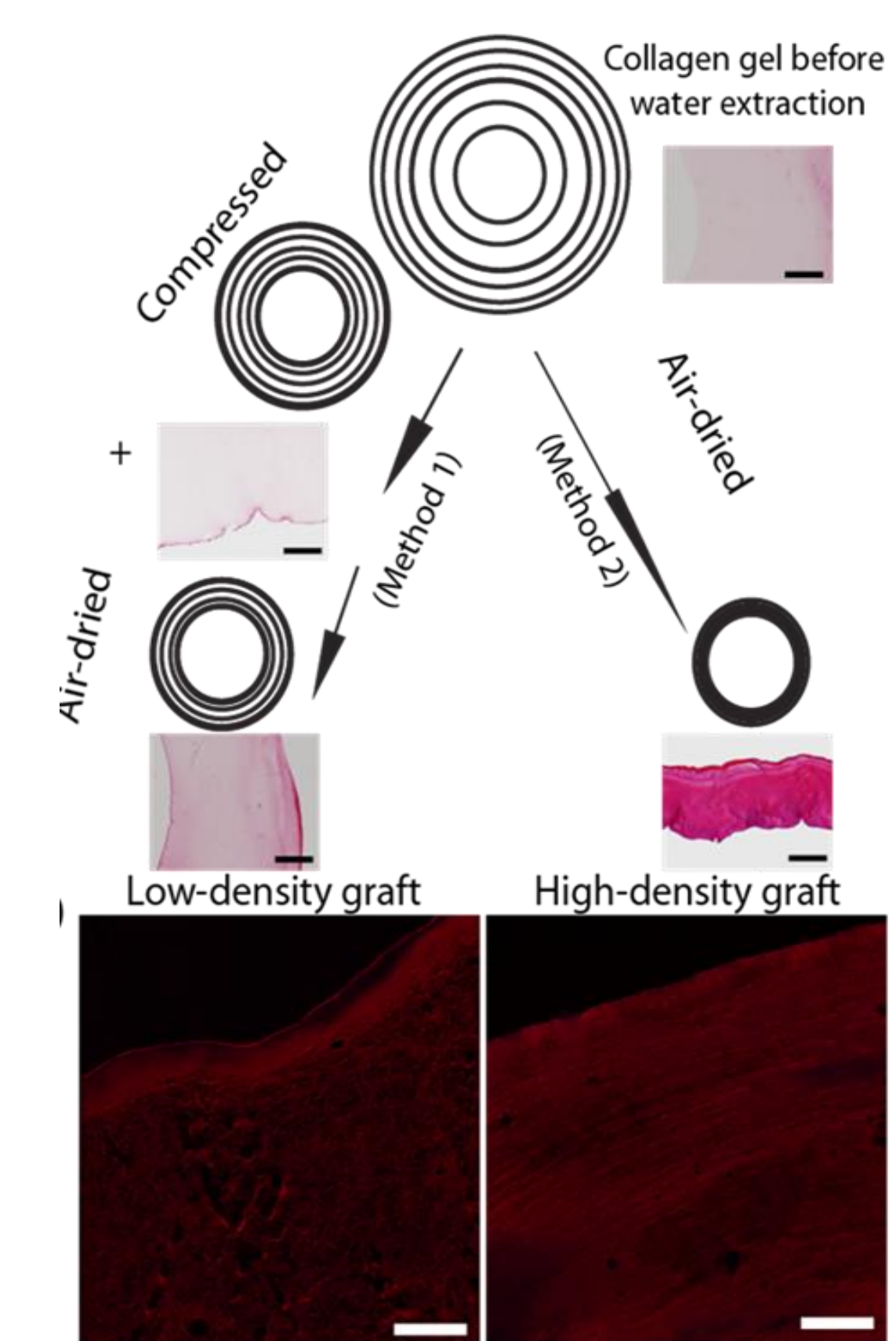


Fig.3: Density gradient tube

Results:

The initial dog from the pilot study had no macroscopic complications, was euthanized at 2 months post-surgery and histology showed regeneration of the implanted site. 2 dogs doing well after 12 months were euthanized after cystoscopy showing macroscopic regeneration. No signs of stenosis nor fistula observed. 6 well doing dogs are kept. One will be euthanized at 6 months and the 5 remaining at 12 months post operative. None of the operated dogs showed macroscopic or clinical complications.

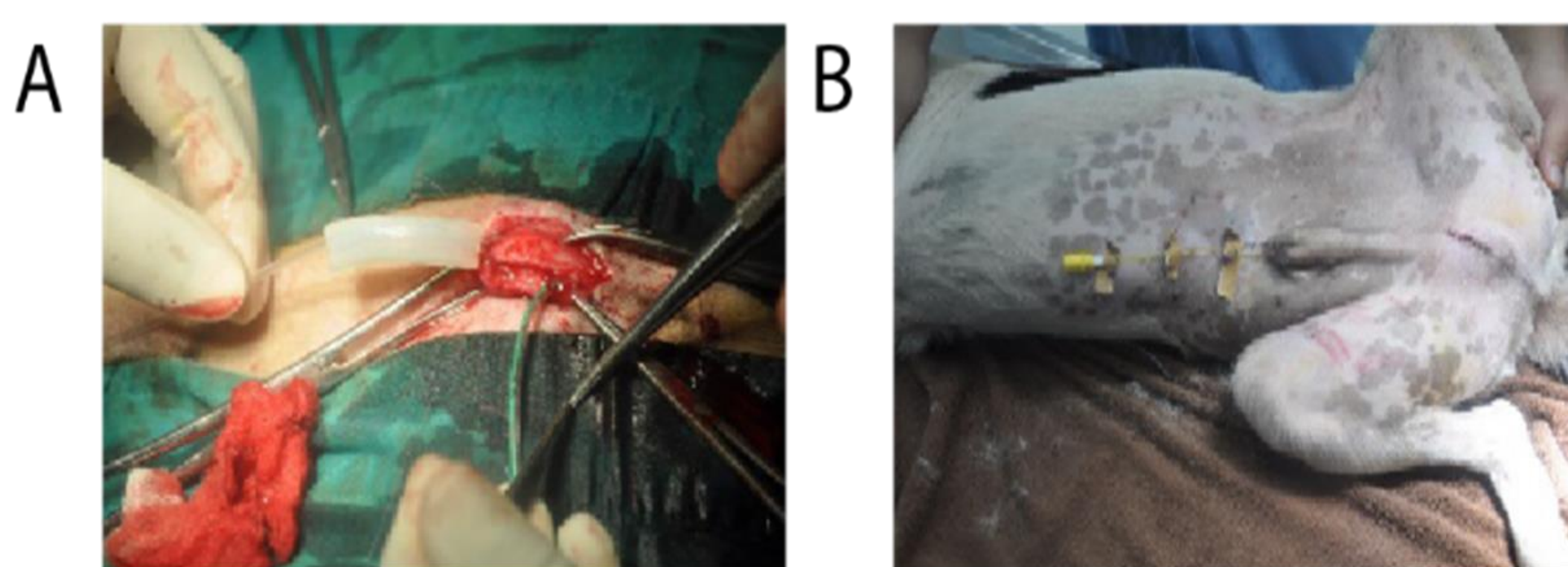


Fig.4: Operated dogs

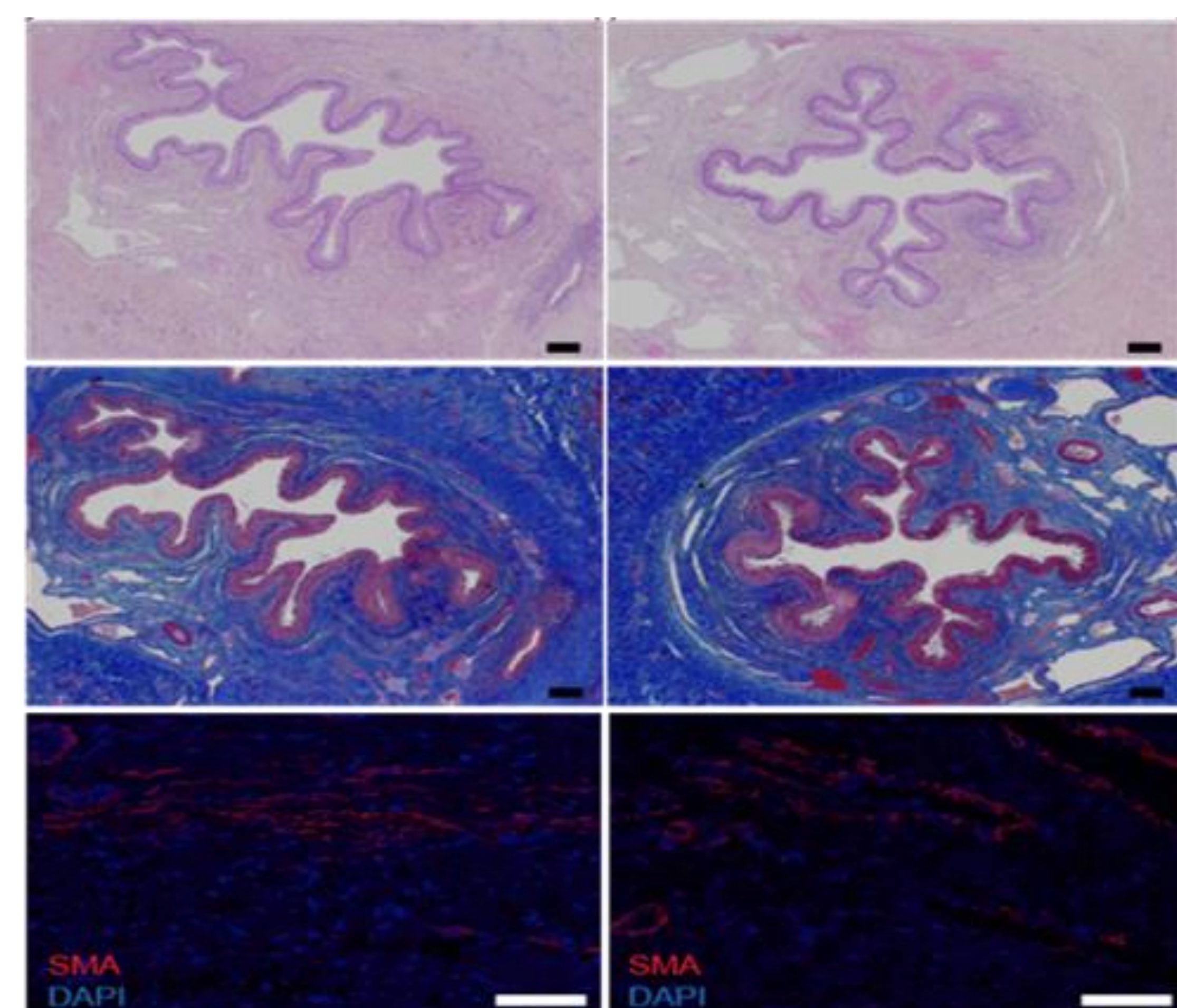


Fig.5: Microscopy at 75 days similar to non operated dog.

Conclusion

This off the shelf graft easy to handle for the surgeon, with high regenerative capacity, safe and cost effective is ideal for urethroplasty. We have shown that this is possible using an acellular platform. The data generated from this study is currently used for human clinical trial application submission. Further studies, using the same general concept, are necessary to show similar results in vaginal reconstruction.