

# DOES THE ANOGENITAL DISTANCE PREDICT OUTCOME OF HYPOSPADIAS REPAIR?

Alexander Springer<sup>1</sup>, Stefan Riedl<sup>2</sup>, Ursula Tonnhöfer<sup>1</sup>, Manuela Hiess<sup>3</sup>, Martin Metzelder<sup>1</sup>, Doris Hebenstreit<sup>4</sup>

<sup>1</sup> Department of Pediatric Surgery, Medical University Vienna, Austria

<sup>2</sup> Department of Pediatrics, Medical University Vienna, Austria

<sup>3</sup> Department of Urology, Medical University Vienna, Austria

<sup>4</sup> Department of Urology, Medical University of Innsbruck, Austria

## Introduction

Recent studies show that the anogenital distance is sexually dimorphic (longer in male). There is experimental evidence that the anogenital distance is androgen action dependent. This distance seems to be shorter in androgen-action related diseases like hypospadias.

## Objective

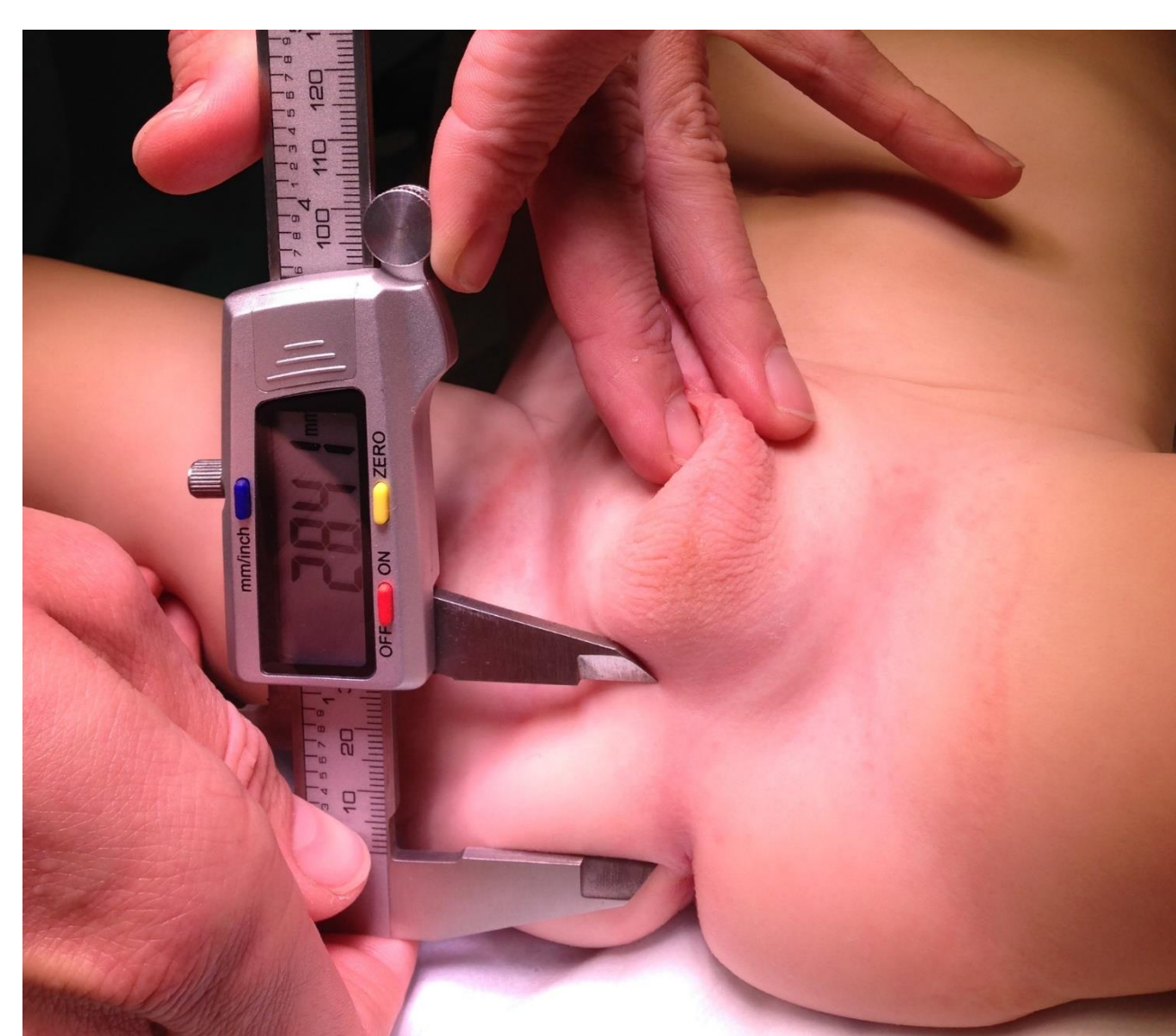In this study we sought to determine whether the anogenital distance is predictive for surgical outcome of hypospadias repair (complications, redo-surgery, staged hypospadias repair).

## Patients and Methods

Ethical approval from Medical University Vienna was obtained. This is a single-center, two surgeons consecutive series. Patients were collected prospectively. AGD was measured in OR prior to surgery by 2 surgeons (blinded, each 3 times), **figure 1**. Outcome parameters were defined as: 1.) complications (fistula, breakdown, glans dehiscence, redo surgery) and 2.) need for staged repair. There were 208 prepubertal boys: 119 controls 2.38yrs (0.02-10.2) and 89 hypospadias (55 distal hypospadias 2.74yrs (0.07-9.67) and 34 proximal hypospadias 2.45yrs (0.58-9.76). Mean follow-up was 1.1yrs.

## Results

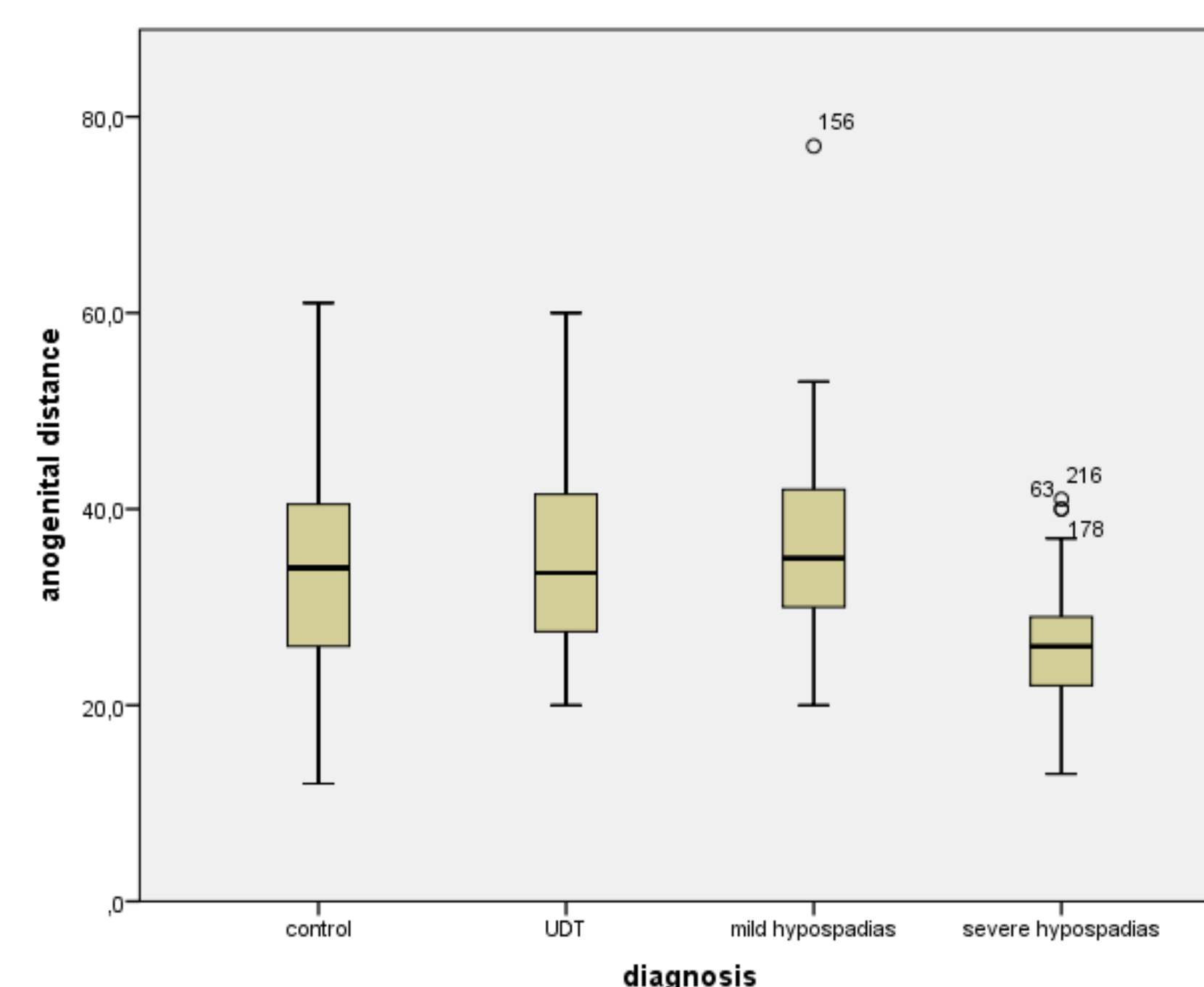
There was no difference in AGD in controls and mild hypospadias. Severe hypospadias had a significantly shorter AGD ( $p=0.003$ ). AGD was significantly shorter in patients undergoing staged repair (37mm vs. 26mm,  $p=0.001$ ). AGD was significantly shorter in patients who developed postoperative complications (38mm vs. 29mm,  $p=0.04$ ).



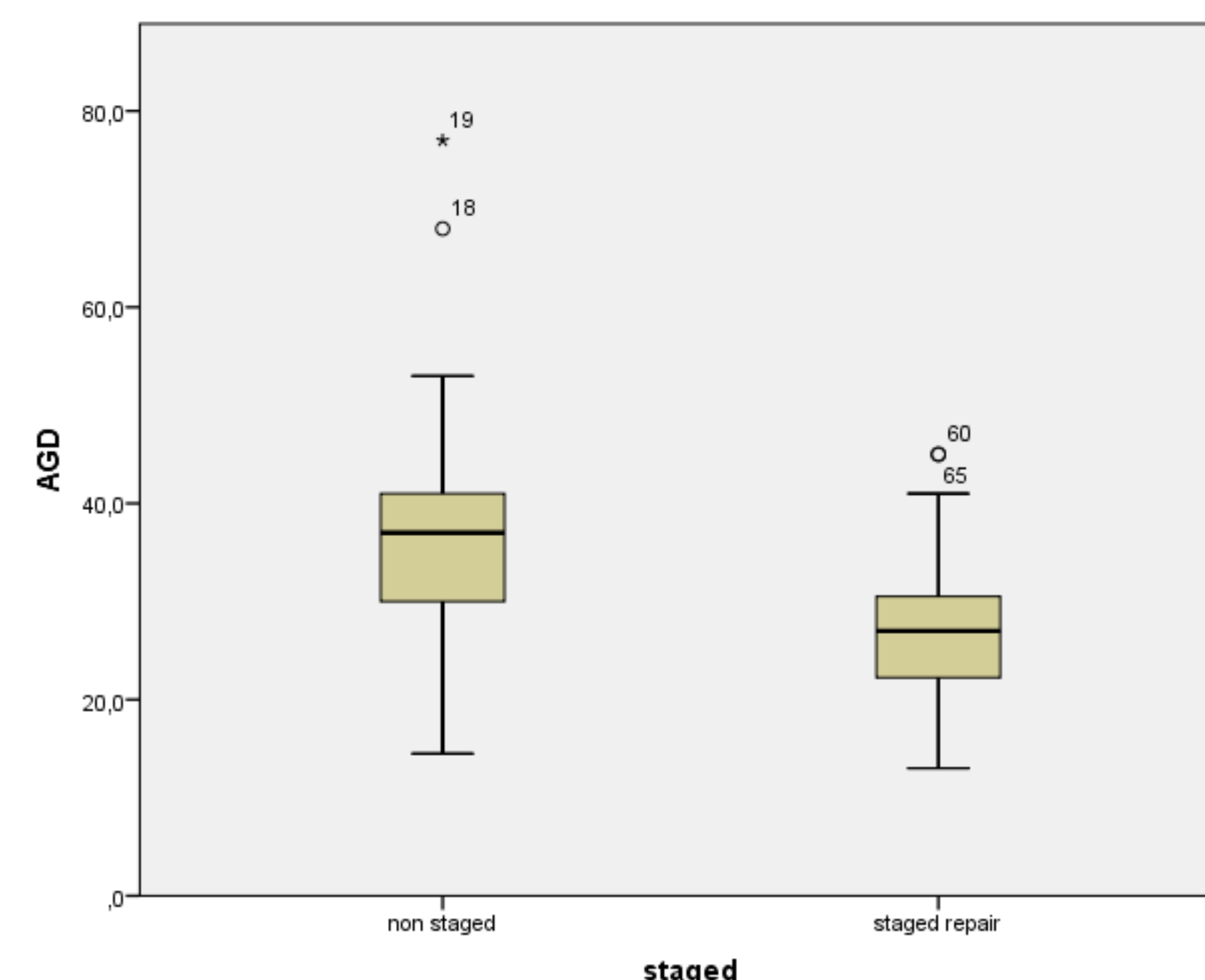
**Figure 1** anogenital distance is measured with minimal intra-observer and inter-observer variance

## Conclusion

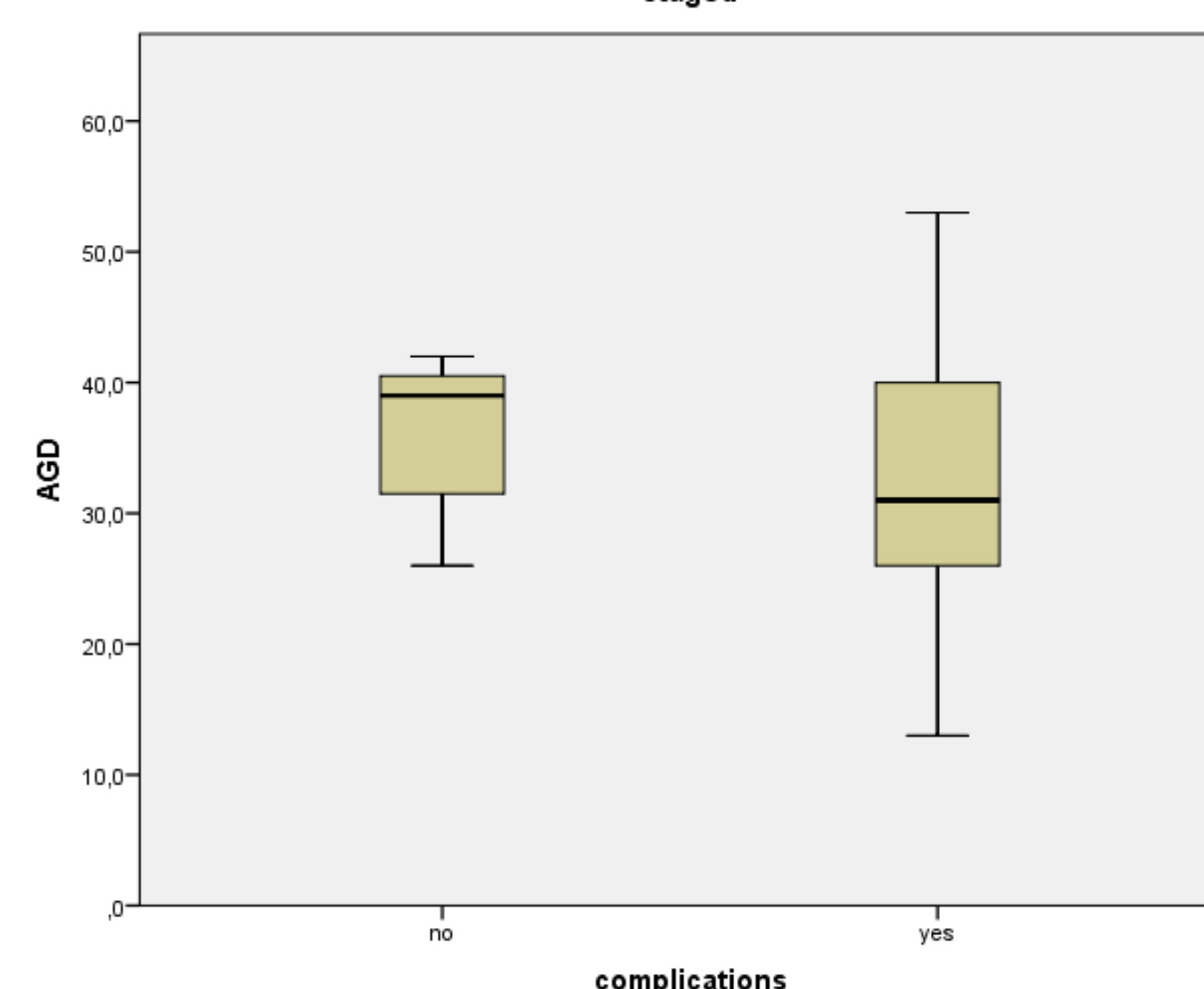
The AGD seems to have predictive value regarding outcome of hypospadias repair. Hypothetically, a short AGD resembles impaired intra uterine androgen action (low androgens, androgen receptor problems, counteracting endocrine disruptors, and unknown genetic androgen interaction). These fetal androgen problems may be reflected in hypospadias minor tissue quality resulting in delayed wound healing, inflammation and a higher complication rate or more difficult surgery resulting in staged repair.



**Figure 2** Anogenital distance in controls, boys with undescended testis, mild and severe hypospadias. Boys with severe hypospadias have a significantly shorter distance ( $p=0.003$ , Kruskal-Wallis)



**Figure 3** Anogenital distance in staged repair is shorter ( $p<0.001$ , Mann-Whitney)



**Figure 4** Anogenital distance in boys with complications is shorter ( $p<0.001$ , Mann-Whitney)

## References

- [1] Li N, Chen X, Zhou X, Zhang W, Yuan J, Feng J. The mechanism underlying dibutyl phthalate induced shortened anogenital distance and hypospadias in rats. *Journal of pediatric surgery*. 2015;50:2078-83.
- [2] Springer A, Spinoit AF, Nappo S, Badawy H, Wallis C, Hoebeke P, et al. Current Best Practice Options in the management of hypospadias. In: DeVries CR, Nijman JM, editors. *Congenital Anomalies in Children - A Joint SIU-ICUD International Consultation*. Montreal: Société Internationale d'Urologie (SIU); 2014. p. 52-78.
- [3] Sathyanarayana S, Grady R, Redmon JB, Ivcekk K, Barrett E, Janssen S, et al. Anogenital distance and penile width measurements in The Infant Development and the Environment Study (TIDES): methods and predictors. *Journal of pediatric urology*. 2015;11:76.e1-6.
- [4] Cox K, Kyriakou A, Amjad B, O'Toole S, Flett ME, Welsh M, et al. Shorter anogenital and anoscrotal distances correlate with the severity of hypospadias: A prospective study. *Journal of pediatric urology*. 2016.
- [5] Singal AK, Jain VG, Gazali Z, Shekhawat P. Shorter anogenital distance correlates with the severity of hypospadias in pre-pubertal boys. *Human reproduction (Oxford, England)*. 2016;31:1406-10.
- [6] Thankamony A, Lek N, Carroll D, Williams M, Dunger DB, Acerini CL, et al. Anogenital distance and penile length in infants with hypospadias or cryptorchidism: comparison with normative data. *Environmental health perspectives*. 2014;122:207-11.

## Contact information

[alexander.springer@meduniwien.ac.at](mailto:alexander.springer@meduniwien.ac.at)

Pediatric Urology Medical University Vienna  
+43(1)40400-19210