

Rare combination with congenital hypothyroidism

Sajith Sandamal, Kamal Weerasinghe, Praveen Jauhari
Wrexham Maelor Hospital, Wrexham, United Kingdom



- Congenital hypothyroidism rarely presents with other organ dysfunction.
- Continued vigilance is essential, especially when other unexplained associations are present which may need further exploration.
- This case report presents a 2 year old girl, who was born to non-consanguineous Afghan parents (migrants to UK), diagnosed with

Brain - Lung - Thyroid syndrome

Hypothyroidism

- She had high TSH on newborn blood spot screening and had further investigations.

Venous TSH level- 31.31 mU/L (Ref. 0.35 – 5.5)	free T4 level - 10.2pmol/L (Ref. 7-17)
Thyroglobulin – 108.8 ug/L (Normal for age)	Isotope scan of thyroid - normal uptake and anatomical position of thyroid

- L-thyroxine treatment was commenced (50ug/day) and reduced to a lower maintenance dose (20 ug/day) with in one month with rapid drop of TSH
- Her requirement of L-thyroxine was kept on the same dose with close follow up of thyroid function bloods.
- Both parents had normal thyroid profiles .

Lungs

- Since 8 weeks of age, she had recurrent chest infections and many of them were bronchiolitis and viral chest infections. Many of them were in her first year of life and few in second year . Most of the hospital admissions needed prolonged oxygen therapy.
- Since second month of age, she developed noisy breathing which was more prominent during chest infection with marked chest recessions

Findings were Normal in - CXR , 2D echo, Naaso fibre endoscopy, Immunoglobulin levels

Brain

In Her Neurological Assessment :

- Global developmental delay since beginning with significant delay in motor domain
- Significant generalised hypotonia
- Subtle dysmorphisms - hypertelorism, upward slanting eyes, low set ears, mid facial hypoplasia, high arched palate
- At age of 2 years she still did not show any movement disorders

Evaluation - MRI brain – structurally normal
Urine organic acid , Serum Ammonia level - Normal
Plasma amino acid – normal

Genetics

Array CGH – Micro-deletion in chromosome 14 (14q13.1q21) which contains 21 OMIM genes, of which five are pathogenic – CFL2, NFKB1A, NKX2-1, PAX9, PSMA6

This seems to be *de novo mutation* as parental genetics did not show this deletion.

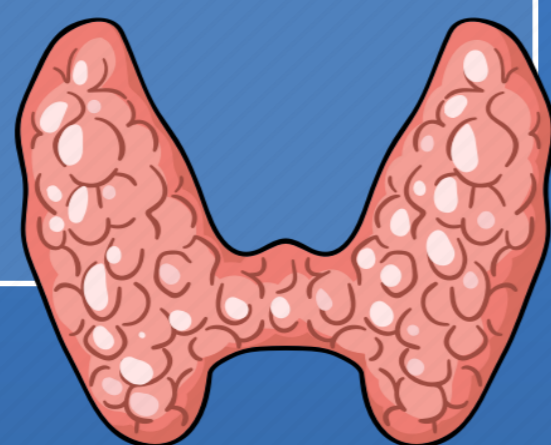Discussion

Haploinsufficiency of NKX2-1 gene - seems to be the culprit for this complex phenotype .

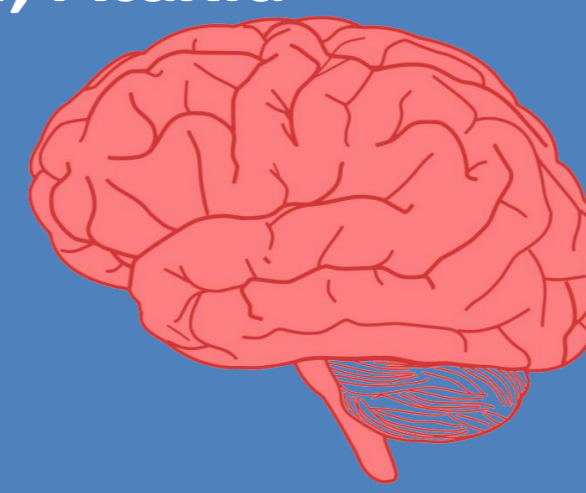This gene mutation caused **Brain-Lung-Thyroid syndrome** characterised by congenital hypothyroidism, infant respiratory distress and benign hereditary chorea.

With the described cases in the literature on this mutation, clinical spectrums of hypothyroidism, respiratory and neurological problems can varied widely.

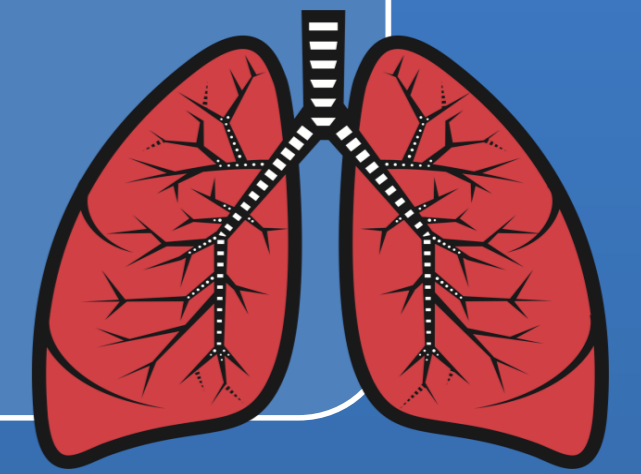
- Hypothyroidism
- Thyroid Agenesis



- Hypotonia
- Motor developmental delay
- Chorea, Myoclonus, Dystonia, Ataxia
- Dysarthria
- Cognitive impairment
- Psychiatric illness



- Neonatal/Infant respiratory distress syndrome
- Recurrent chest infection
- Obstructive airway disease
- Chronic interstitial lung disease



There is a strong association with **Benign hereditary chorea** and **NKX2-1** gene mutations, still the 2 year old index kid did not show any abnormal movements .

PAX9 gene defects can associate with oligodontia and this girl's teeth seems under developed .

Conclusion

When congenital hypothyroidism presents in the contexts of respiratory or neurological problems , it is worth to review genetics for NKX2-1 gene mutations.

This interesting case highlights that importance of further investigations, when we encounter unexplained and unusual clinical combination with congenital hypothyroidism

- Reference: 1. <https://omim.org/entry/600635> , NK2 HOMEBOX 1; NKX2-1
2. **Benign hereditary chorea: an update.** Peall, Kathryn and Kurian, Manju . *Tremor and Other Hyperkinet Movements* 2015 , 3. 10.7916
3. **Five new TTF1/NKX2.1 mutations in brain-lung-thyroid syndrome: rescue by PAX8 synergism in one case**
Aurore Carré et al *Human Molecular Genetics*, Volume 18, Issue 12, 15 June 2009, Pages 2266–2276

