

CONGENITAL HYPOPITUITARISM: THE ROLE OF GENETICS

E. GIL-POCH¹, F.J. ARROYO-DÍEZ¹, P. MÉNDEZ-PÉREZ² and E. GALÁN-GÓMEZ²

1. Paediatric Endocrinology, Pediatric University Hospital, Badajoz, Spain.

2. Clinical Genetics Unit, Pediatric University Hospital, Badajoz, Spain.

PITUITARY, NEUROENDOCRINOLOGY AND PUBERTY

INTRODUCTION

Hypopituitarism refers to the insufficient secretion of one or more pituitary hormones.

If default is present at the time of birth is called **congenital hypopituitarism (CH)**. Causes of this are perinatal pathology and genetic alterations.

The clinical presentation is heterogeneous. **The diagnosis is made by clinical suspicion supported by hormonal determinations, brain imaging test (MRI) searching of structural defects and genetic study.**

GENETICS

The development of the pituitary gland is a complex process regulated by specific transcription factors.

Mutations in precursor genes result in different degrees of hypopituitarism, which may be associated genes are **PROP1, POU1F1, LHX3, LHX4 and HESX1**. In recent years, due to advances in genetic sequencing techniques, a large number of genes associated with etiology of CH have been known.

The type of inheritance shows great variability.

We present the cases of **two pairs of siblings affected by CH of genetic etiology.**

CLINICAL PRESENTATION

Case 1

Patient 1

24-month-old-male patient, under study for short stature, an imaging test (MRI) is performed, in which structural alteration of the pituitary area is observed (pituitary hypoplasia, absence of pituitary stalk and ectopic neurohypophysis). In the genetic study there was a **heterozygous pathogenic mutation in GLI2 gene**.

Patient 2

His younger brother also shows short stature, the directed study was carried out, with a **heterozygous pathogenic mutation of the same gene**. The MRI showed the same structural alteration as his brother.

The family genetic study revealed that the **mother of both is a carrier of the pathogenic mutation**.

*This family received **genetic counseling** and a third brother was born after selection embryo in which the genetic mutation is not present.*

Case 2

Patient 1

21-month-old female patient, under study due to short stature and hypoglycemia. She had a history of congenital strabismus. The imaging study shows a structural alteration of the pituitary gland and a **disturbance in FOXA2 gene** in the genetic study (heterozygous pathogenic mutation).

Patient 2

A study was carried out on his 7-month-old brother with short stature and hypoglycemia, **with an alteration in the same gene** and the same imaging at pituitary gland.

The family genetic study revealed that the **father of both is a carrier of the pathogenic mutation**.

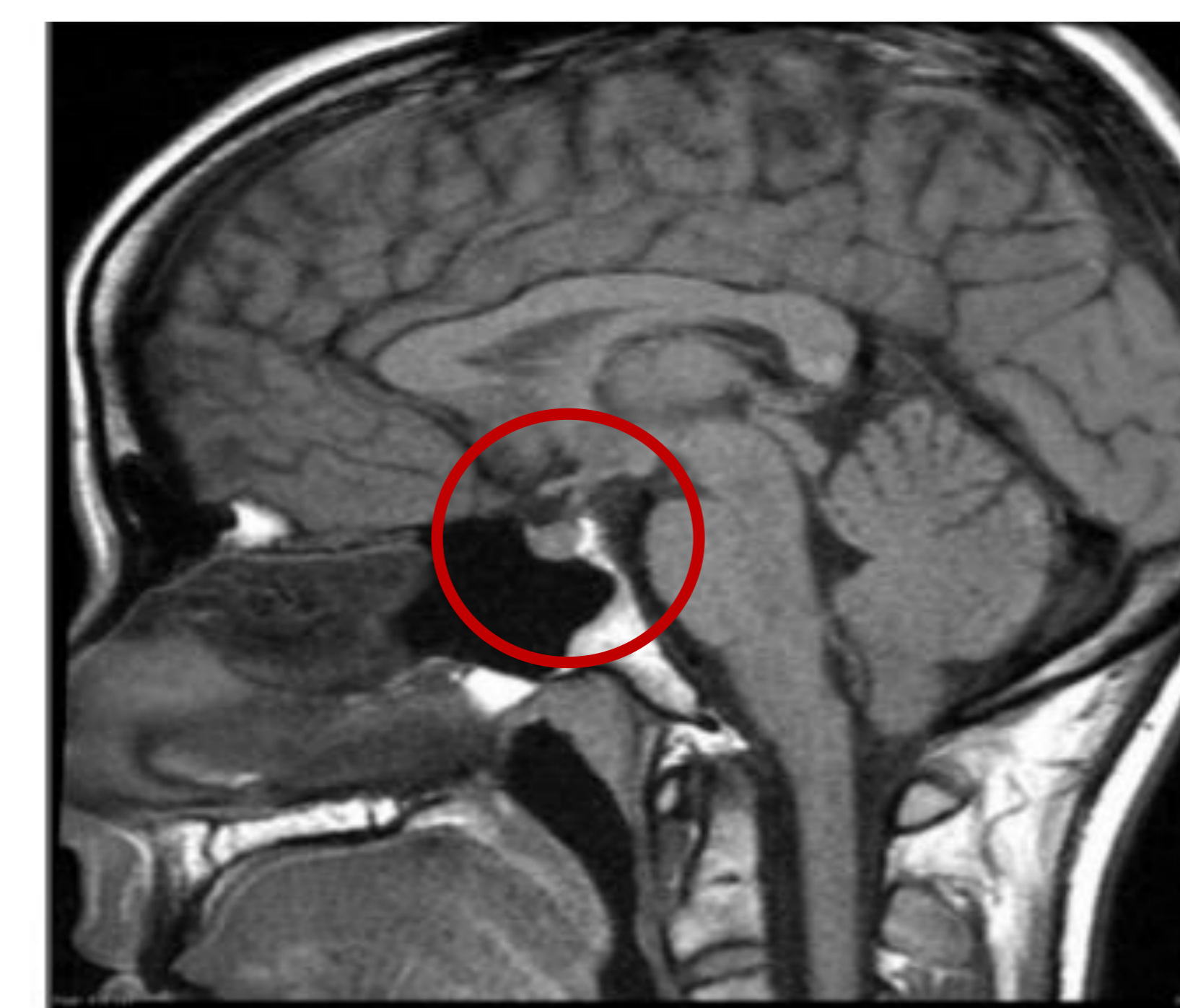

Figure 1. Normal pituitary area.

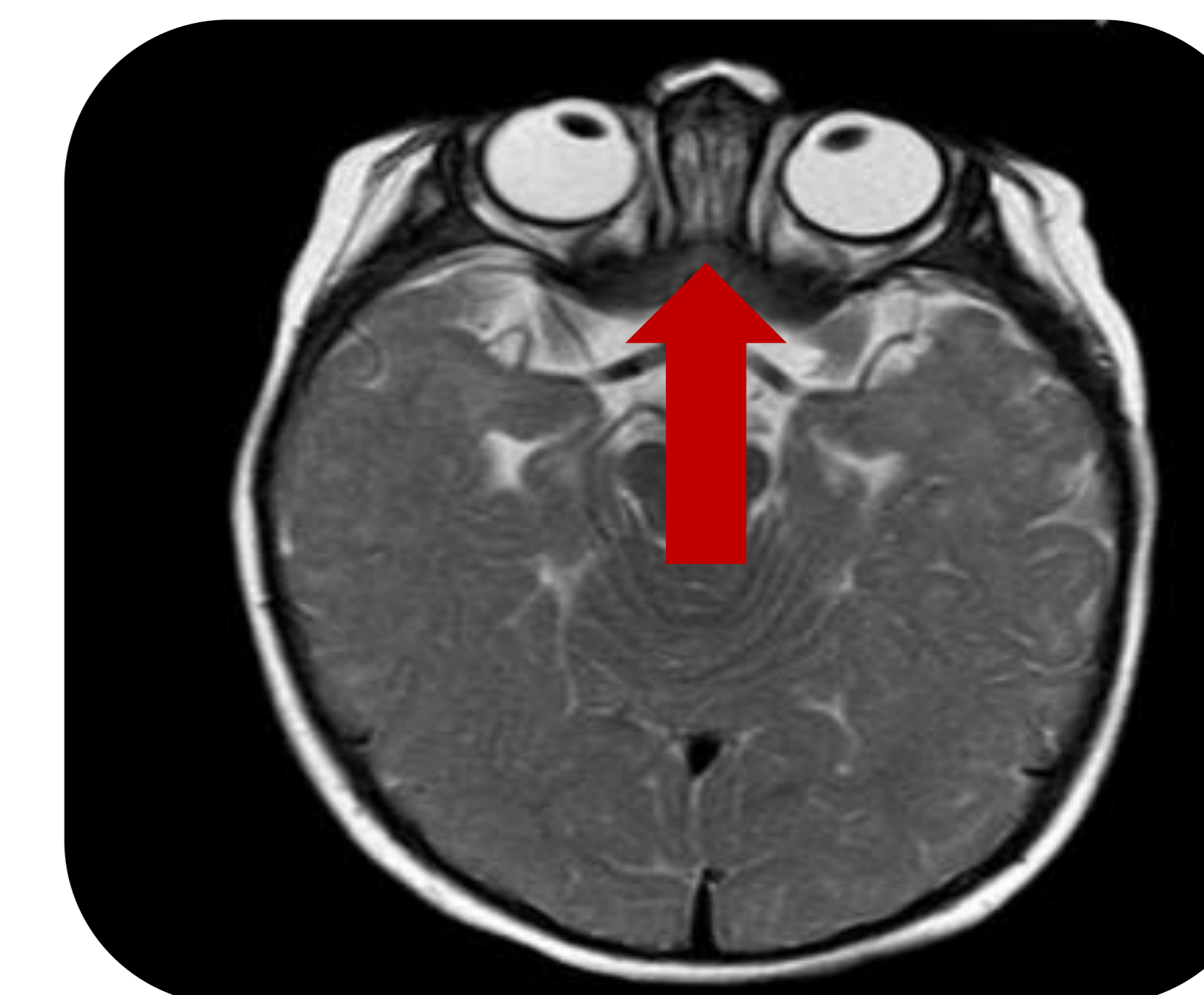


Figure 3. Congenital strabismus.

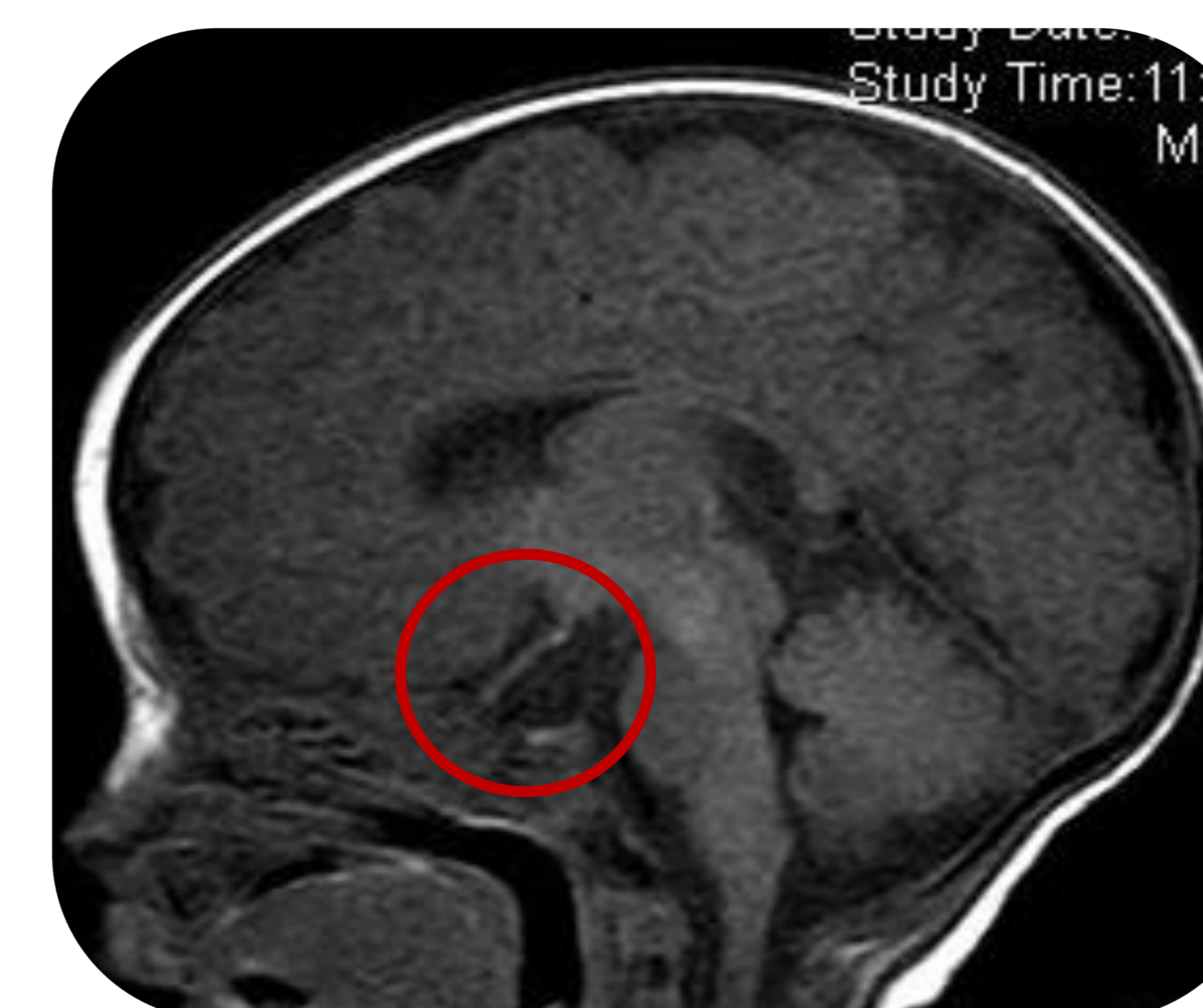

Figure 2. Structural alteration of the pituitary area: pituitary hypoplasia, absence of pituitary stalk and ectopic neurohypophysis.

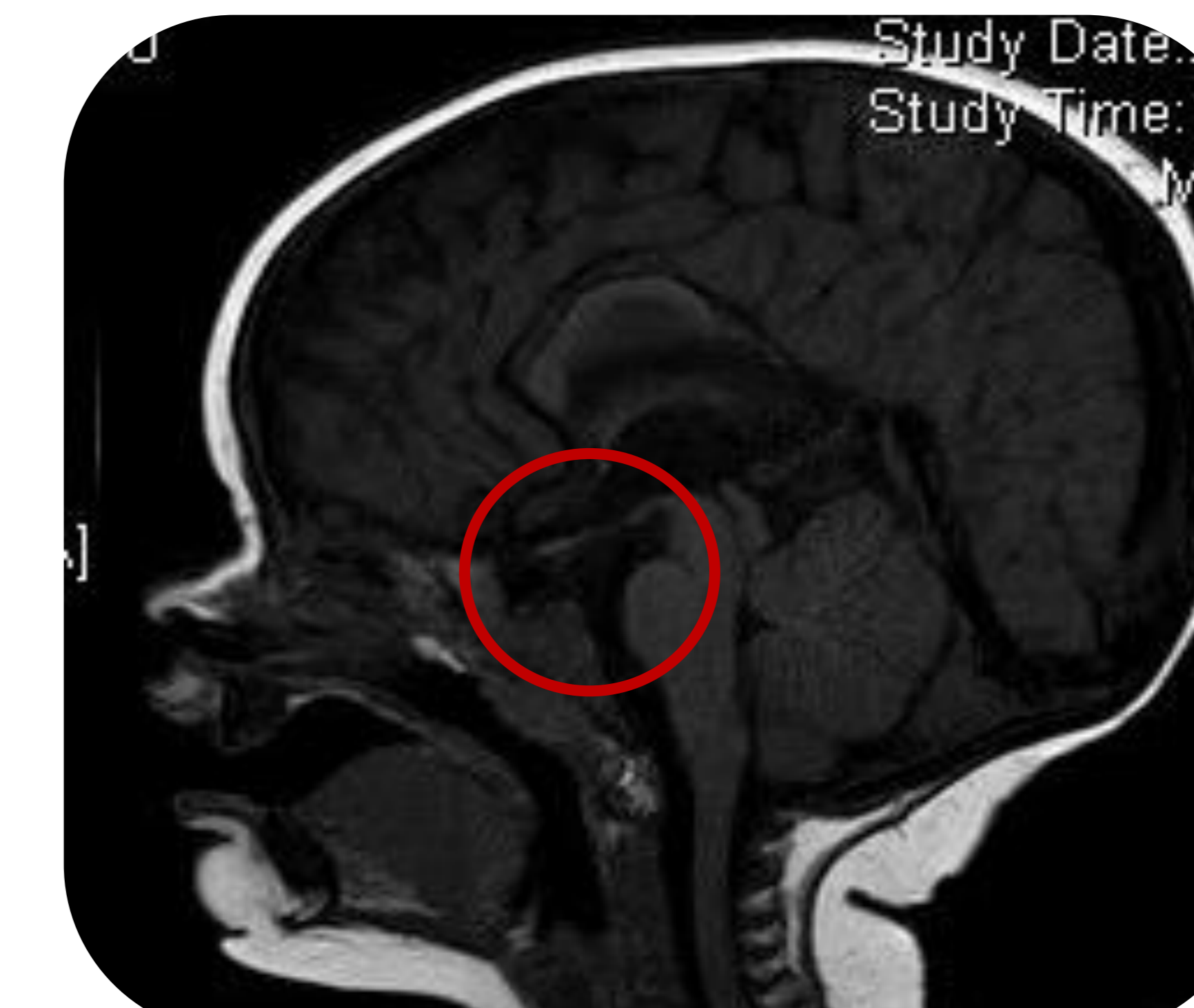


Figure 4. Structural alteration of the pituitary area: pituitary hypoplasia, absence of pituitary stalk and ectopic neurohypophysis.

CONCLUSIONS

In both cases, the similar clinical presentation in the siblings allowed us to **conduct a directed family genetic study of the affected genes**.

The most appropriate approach to the study of the genetic etiology of CH should be through **massive sequencing studies**, with caution at interpreting the results and approaching a possible **family study and genetic counseling**.

REFERENCES

- Palomo Atance E, Rodríguez Contreras FJ. Déficit combinado de hormonas hipofisarias. Manual diagnóstico y Terapéutica de Endocrinología Pediátrica. H. La Paz.
- Gregory LC, Dattani MT. The Molecular Basis of Congenital Hypopituitarism and Related Disorders. *J Clin Endocrinol Metab*. 2020; 105(6):dgz184. [PubMed]. doi: <https://doi.org/10.1210/clinem/dgz184>.
- Dattani MT. Congenital Hypopituitarism, novel phenotypes, novel mechanism. *Rev Esp Endocrinol Pediatr* 2020; 11 suppl(1):26-38. doi: 10.3266/RevEspEndocrinolPediatr.pre2020.Sep.610
- Céspedes C, Murillo A, Forero C. Hipopituitarismo congénito: reporte de caso y revisión de la literatura. *Rev Esp Endocrinol Pediatr* 2017; volumen 8. Edición 1. doi: 10.3266/RevEspEndocrinolPediatr.pre2017.Mar.376

CONTACT INFORMATION

Estela Gil Poch

Paediatric Endocrinology, Pediatric University Hospital, Badajoz, Spain.

e-mail address: estela.gil@salud-juntaex.es

