

# USE OF TOLVAPTAN IN A CHILD WITH SIADH POST PITUITARY SURGERY

N. LOHIYA<sup>1</sup>, M. DIDI<sup>1</sup> and S SENNIAPPAN<sup>1</sup>

1. Department of Endocrinology, Alder Hey Children Hospital, Liverpool, United Kingdom

## BACKGROUND

- Suprasellar mass and surgery of pituitary tumor is a challenge, in particular fluid management is critical.
- The triphasic response an initial phase of Central DI (CDI) followed by a second phase of transient Syndrome of Inappropriate Anti-Diuretic Hormone (SIADH) and the third and the final phase of permanent CDI.
- The gold standard for SIADH management is fluid restriction
- Fluid restriction and hypertonic saline may not be adequate to control the hyponatremia and water imbalance in SIADH
- V2 receptor antagonist (vaptans) act by the mechanism of competitive antagonism blocking the binding of ADH to V2 receptors in the renal collecting duct. This prevents free water absorption, thus increasing the urine output.

## CASE DESCRIPTION

- A suprasellar mass around the pituitary stalk was also removed.
- The pre-operative and post-operative endocrine evaluation is shown in the table 1. ACTH suppressed (<1.1pmol/L) with low cortisol 123 nmol/L. Hence, he was commenced on oral hydrocortisone.
- After 12 hours of surgery serum osmolality was high with low urine osmolality indicating DI and was managed with intravenous desmopressin.
- From post-operative day 5, the urine output started to fall and serum osmolality reduced with increased urine SIADH. Fluids were restricted to half the maintenance.
- By day 6 the fluid restriction was further reduced to 30% and 1.8% saline. At this time a dose of furosemide was used showing no response.
- Hence, a single dose of oral tolvapan (15 mg) was given following which the serum sodium and osmolality steadily improved with increase in the urine output and drop in the urine osmolality as shown in Fig 1 & 2
- From day 8 urine osmolality reduced and there was polyuria, hypernatremia with high serum osmolality.
- Suggestive of DI and oral desmopressin was started and optimized to 120 mcg twice daily.

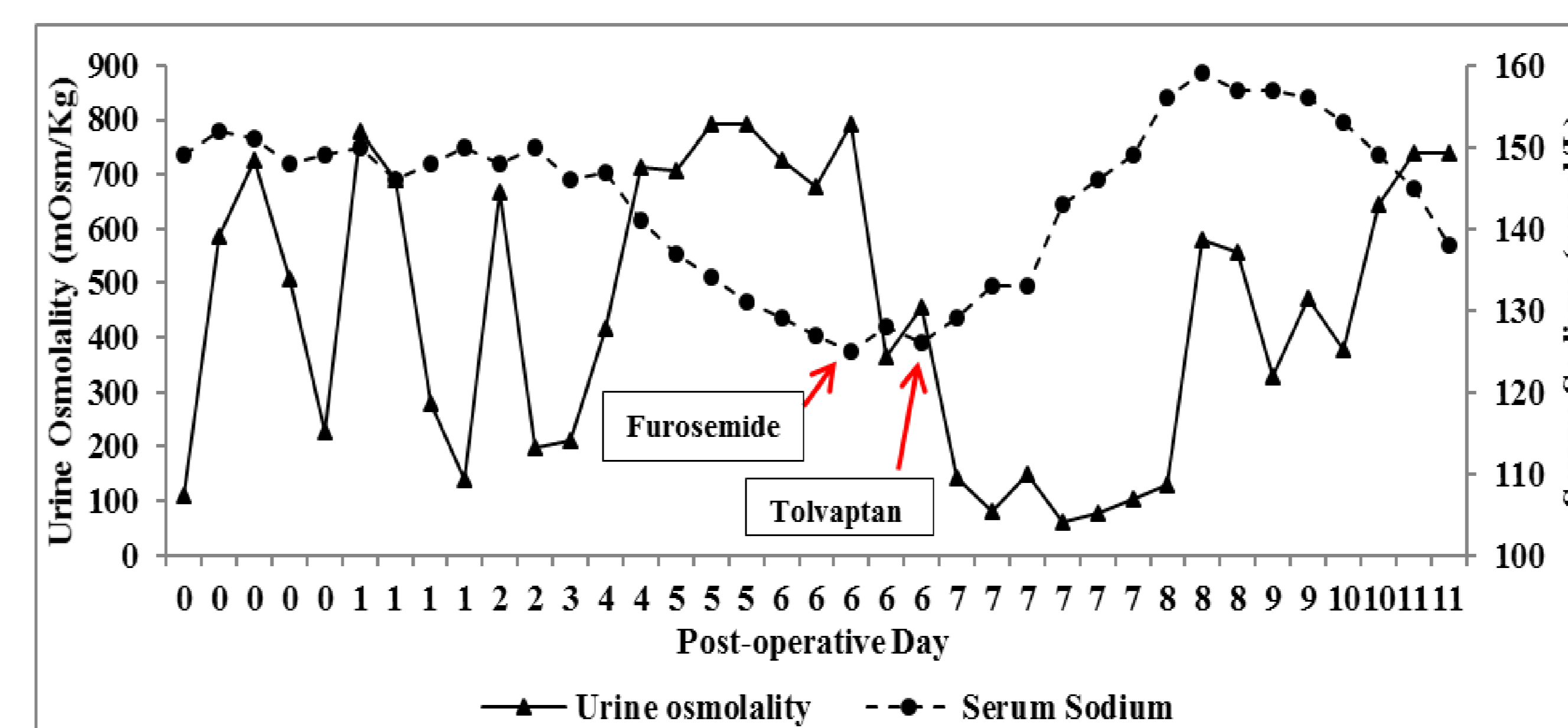


Fig 1. Serum Sodium and Urine Osmolality of the patient during the post-operative period demonstrating a triphasic response. The use of furosemide and Tolvaptan during the phase of SIADH is indicated in the graph.

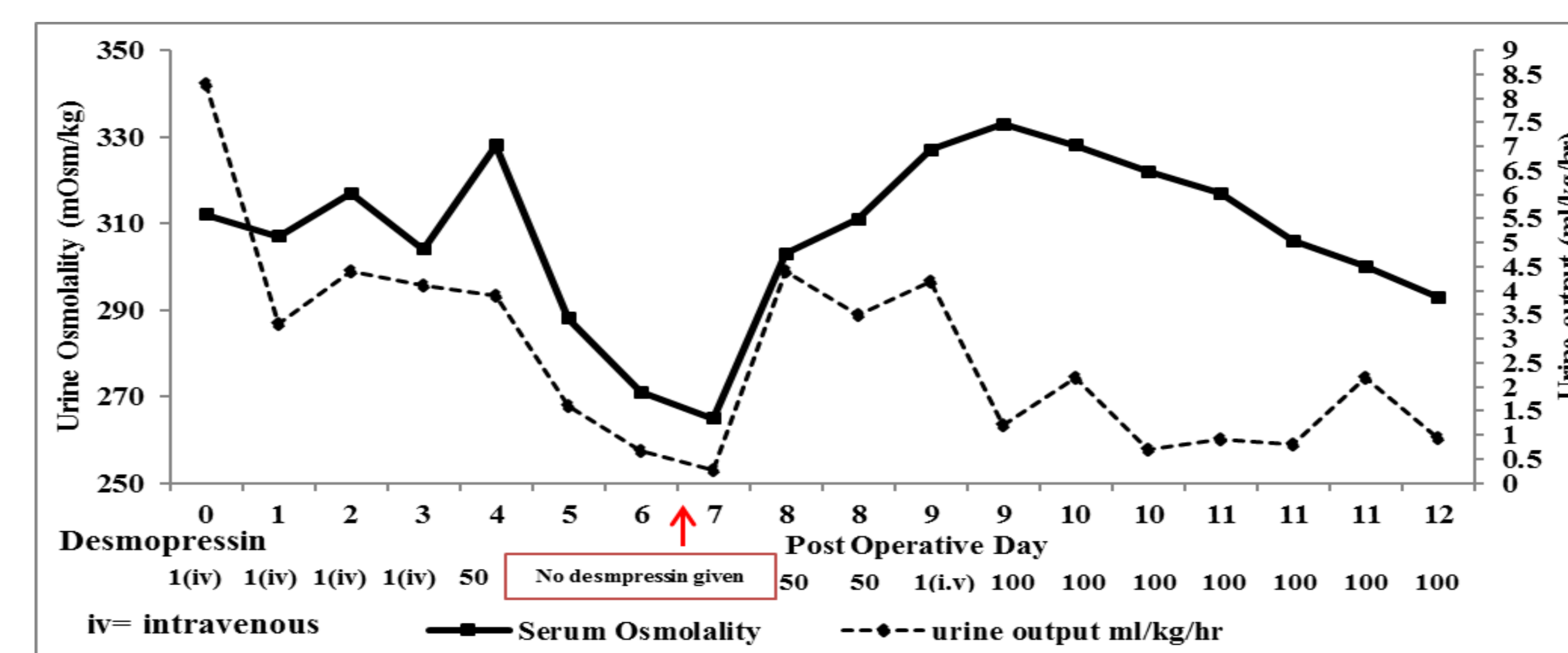


Fig 2. Serum Osmolality and Urine output of the patient during the post-operative period demonstrating a triphasic response. The arrow indicate the point of Tolvaptan use.

Biochemical Parameter	Pre-operative	Post-operative (Day 3)
TSH (0.3-3.8 mu/L)	0.41	1.06
Free T4 (9-19 pmol/L)	15.9	10.1
LH (IU/L)	5	0.3
FSH (IU/L)	2.4	0.4
Testosterone nmol/L	3.3	<0.7
Prolactin (0-350 mU/L)	293	--
IGF-1 (22.5-65.9 nmol/L)	27.8	9.5
Cortisol (140-500 nmol/L)	123	--
ACTH (2-11 pmol/L)	<1.1	<1.1
B-HCG (0-10 IU/L)	<1	--
AFP (0-7 IU/ml)	1.5	--

Table 1. Pre-operative (suprasellar mass removal) and Post-operative endocrine biochemistry of the child

## CASE DESCRIPTION

- A 15 yr old boy presented with history of progressive headache, ataxia, decreased vision and vomiting.
- On examination, there was bilateral nystagmus with bilateral papilledema.
- His weight was 93.2 kg (+4.2SDS).
- MRI head showed a posterior fossa tumor 7.7x3.4x5 cm along with a second lesion as a third ventricle tumor measuring 1.8x1.8x1.8cm homogenous iso-intense to cortex on T2 weighted imaging.
- Cerebellar mass was removed and histopathology confirmed it to be a medulloblastoma.

## CONCLUSIONS

- We present a patient of post-suprasellar mass surgery presenting with the triphasic phenomenon of water imbalance where the phase of transient SIADH was successfully managed with Tolvaptan
- Tolvaptan can be a potential treatment option in SIADH resistant to water restriction and hypertonic saline resistant among children and adolescents

## REFERENCES

- Edate S, Albanese A. Management of electrolyte and fluid disorders after brain surgery for pituitary/suprasellar tumours. *Horm Res Paediatr.* 2015;83(5):293–301.
- Tuli G, Matarazzo P, de Sanctis L. Clinical approach to sodium homeostasis disorders in children with pituitary-suprasellar tumors. *Neuroendocrinology.* 2019 Aug 12. doi: 10.1159/000502609
- Peters S, Kuhn R, Gardner B, Bernard P. Use of conivaptan for refractory syndrome of inappropriate secretion of antidiuretic hormone in a pediatric patient. *Pediatr Emerg Care* 2013;29:230-232.
- Tuli G, Tessaris D, Einaudi S, De Sanctis L, Matarazzo P. Tolvaptan Treatment in Children with Chronic Hyponatremia due to Inappropriate Antidiuretic Hormone Secretion: A Report of Three Cases. *J Clin Res Pediatr Endocrinol* 2017;9:288-292.

## ACKNOWLEDGEMENTS

The work was done during ESPE fellowship at Alder Hey Children's Hospital sponsored by Merck.

## CONTACT INFORMATION

Dr Nikhil Lohiya- [drnlohiya@gmail.com](mailto:drnlohiya@gmail.com)

Dr Senthil Senniappan- [senthil.senniappan@alderhey.nhs.uk](mailto:senthil.senniappan@alderhey.nhs.uk)

