

# TWO SISTERS WITH PRIMARY HYPERGONADOTROPIC HYPOGONADISM, PUBERTAL PROGRESS AND DELETION OF 61.5MB OF Xq21.33q28 REGION

E. Dikaiakou<sup>1</sup>, E. A. Vlachopapadopoulou<sup>1</sup>, I. Papoulidis<sup>2</sup>, E. Manolakos<sup>2</sup>, M. Vakaki<sup>3</sup>, S. Michalacos<sup>1</sup>

<sup>1</sup>Dept. of Endocrinology-Growth and Development, Children's Hospital P. & A. Kyriakou, Athens, Greece

<sup>2</sup>ATG Clinical Laboratory Genetics, Athens, Greece

<sup>3</sup>Radiology Department, Children's Hospital P. & A. Kyriakou, Athens, Greece

## INTRODUCTION

Hypergonadotropic hypogonadism is characterized by small gonadal size, low serum concentrations of gonadal steroids, and elevated LH and FSH. Causes include genetic syndromes, i.e. Turner, gonadotoxicity from chemotherapy or radiotherapy, autoimmune or post-infectious injury. Rarely, it is caused by defects in the molecular structure of LH and FSH or defects in their membrane receptors on gonadal cells.

## AIM

To present the novel finding of hypergonadotropic hypogonadism, pubertal progress and molecular alterations in two sisters with variable phenotype.

## METHODS

**Two Greek sisters were investigated.**

**The eldest** was referred for investigation of short stature, at the age of 9 and 5/12 years. There was no positive family history for short stature or other significant pathology.

**Physical examination** revealed no dysmorphic features, and she was prepubertal. She was diagnosed with growth hormone deficiency, for which she receives growth hormone replacement therapy with good response to treatment and normal height at present (10%ile).

**At the age of eleven years** she had breast enlargement, however, laboratory investigation, revealed **hypergonadotropic hypogonadism**, (FSH 31.24 m IU /ml LH 5.44 m IU /ml, estradiol 12.6 pg/ml).

## RESULTS

**Her karyotype was female 46, X, der (X) t (X; 20) (q21.3; p12.3), mat.**

**Mother's karyotype was 46,XX,t(X;20)(q21.32;p12.3)**

**Her sister who, at the age of 10 years, was of normal height and prepubertal, was also investigated.**

**She had elevated gonadotropins and the same karyotype as her older sister:**

**Ultrasound and magnetic resonance imaging of the uterus and ovaries in both sisters showed a similar picture.**

The right ovary was recognized with a cystic formation of 0.91 ml in the presence of an intact follicle, while on the left, fibrous tissue was recognized at the site of the left ovary (0.16 ml).

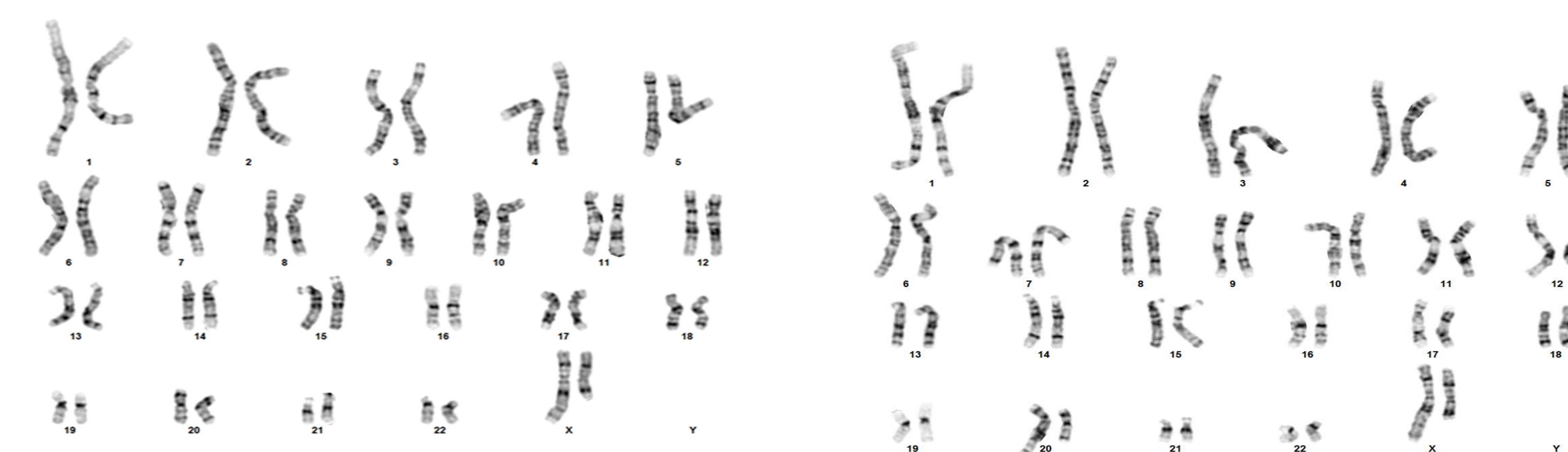
In the younger sister the left ovary was not recognized.

**Array-CGH analysis in both girls detected a genomic pattern of female sex and the presence of:**

**A) a size duplication ~ 8 megabases of the chromosomal region 20p13p12.3 (chr20: 60,747\_8,117,942) that includes the OMIM database 76 genes.**

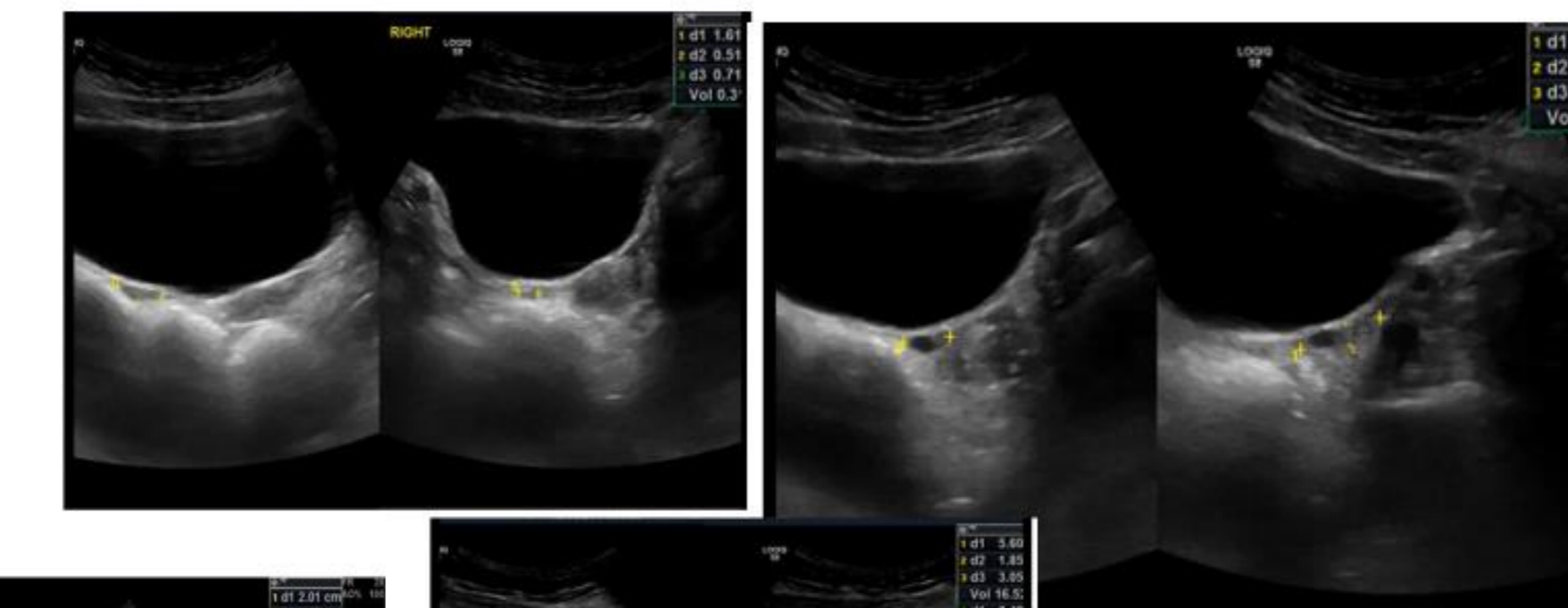
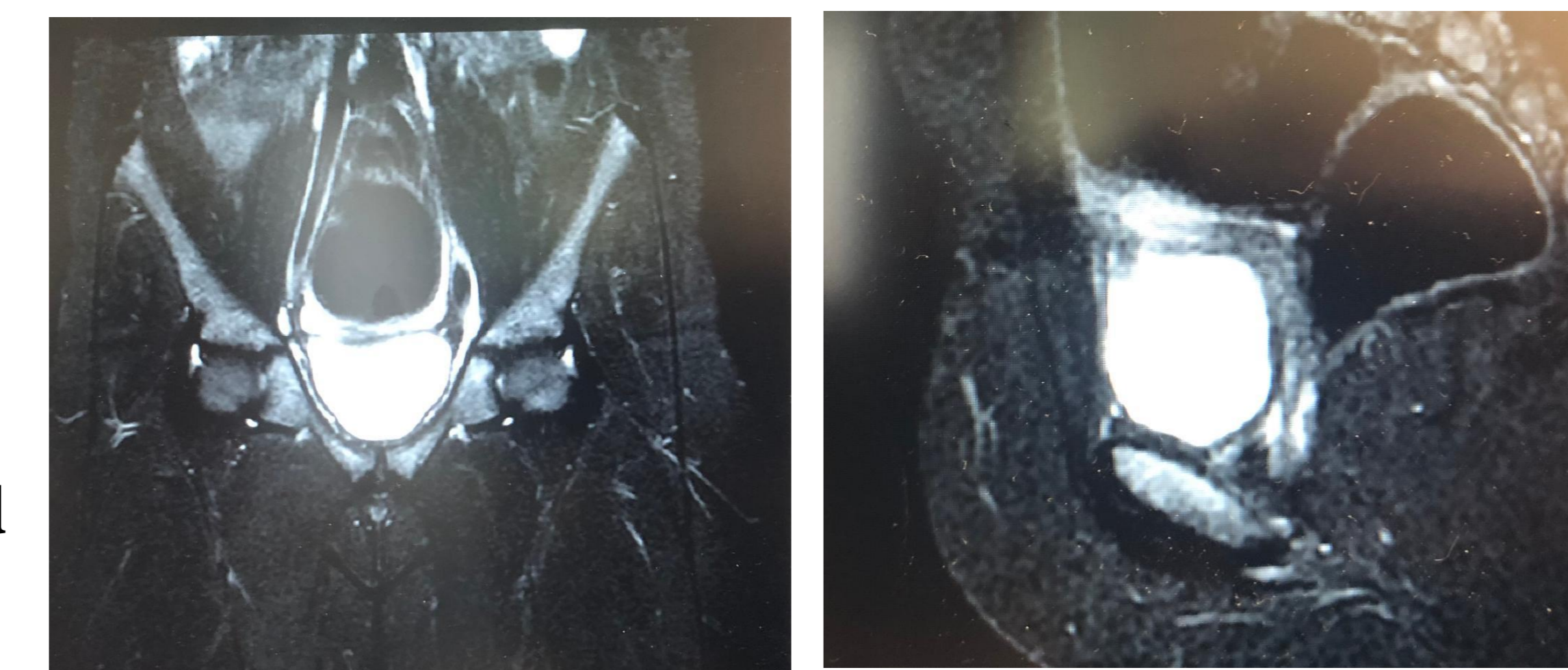
**B) a deletion ~ 61.5 megabases of the chromosomal region Xq21.33q28 (chrX: 93,622,826\_155,226,073) which includes, according to the OMIM database, 102 genes**

Despite hypoplastic ovaries, the older patient at the age of 12.5 years had menarche. The laboratory results at this age were FSH 35.86 mIU / ml, LH 59.95 mIU / ml, Estradiol 173.9 pg / ml, antimullerian hormone <0.01 ng / mL.

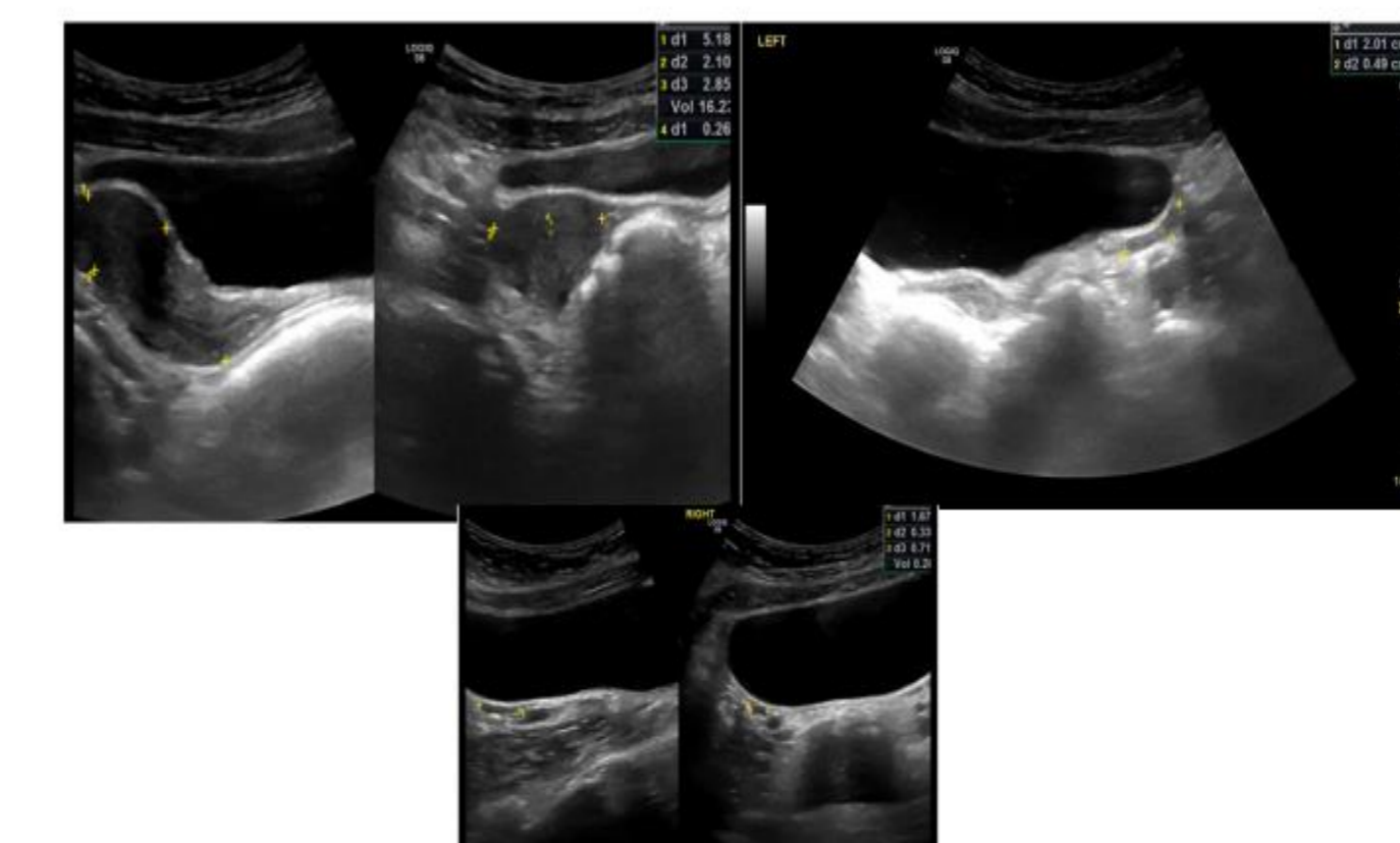


BOTH SISTERS

MOTHER



OLDER SISTER POST MENARCHE



YOUNGER SISTER

	YOUNGER SISTER	Results before menarche	OLDER SISTER	Results before menarche	Post menarche
LH mIU/ml		7,8		>10 ng/ml	
FSH mIU/ml		53,77		148,7	433,4
ESTRADIOL pg/ml		<10		5,44 / 15,54	31,62 / 59,95
				31,24 / 69,43	59,44 / 35,86
				12,6 / 5,34	13,06 / 173,9
				AMH ng / mL.	<0,01

## CONCLUSIONS

**Regarding duplication on chromosome 20** there is a very limited number of individuals with similar finding in the chromosomal region 20p13p12.3. This chromosomal region is part of a wider region, duplication of which, has been associated with mental and developmental delay and congenital deformations. However, most patients described, carry greater duplications compared to the present finding. Our patients are of normal intelligence.

**The X chromosome deletion** is related to the clinical features of the subject, as similar rearrangements of the X chromosome have been described in female subjects with clinical features of Turner syndrome and include primary or secondary amenorrhea and infertility. The event of menarche was unexpected, but it is known that menarche can occur even with 10 % of ovarian function.

The two sisters with genomic pattern of female sex arr[hg19] 20p13p12.3(20:60,747\_8,117,942) x3, Xq21.33q28(93,622,826\_155,226,073)x1, had normal intelligence and although they demonstrated hypoplastic ovaries and elevated gonadotropin levels had spontaneous menarche.

To our knowledge, there are no reports of individuals carrying both findings. Regular monitoring of the patients is required in order to elucidate the evolution of the phenotype.

## REFERENCES

1. Database of Chromosomal Imbalance and Phenotype in Humans Using Ensembl Resources (<http://decipher.sanger.ac.uk/>)

## ACKNOWLEDGEMENTS

Special thanks to I. Papoulidis and E. Manolakos and their laboratory, who helped us with genetic testing and the interpretation of the results.

## CONTACT INFORMATION

Elpis Vlachopapadopoulou, email: [elpis.vl@gmail.com](mailto:elpis.vl@gmail.com)