


THE USE OF INTRAVENOUS INTRODUCTION OF GLUCOCORTICOIDS IN THE ACTIVE STAGE OF GRAVES' OPHTHALMOPATHY IN CHILDHOOD. CLINICAL CASE.

Tatiana E. Ivannikova, Elena V. Nagaeva, Olga B. Bezlepkina
Endocrinology Research Centre, Moscow



INTRODUCTION

Graves' ophthalmopathy (GO) is an autoimmune inflammatory disease of the retrobulbar tissue and oculomotor muscles associated with Graves' disease (GD). The incidence of GO in children is 0.79–6.5:100,000 per year. Some studies indicate that in the treatment of the active stage of GO, intravenous introduction of high doses of glucocorticoids is more effective and has fewer side effects compared to oral administration.

CLINICAL CASE

A 17 year-old patient was observed with a diagnosis of GD in October 2016. When the patient was examined in October 2016 in the hormonal profile there was hyperthyroidism, a high titer of antibodies to the TSH receptor, in connection of which thyrostatic therapy was initiated.

In dynamics since November 2018, there has been a pronounced increase in the total volume of the thyroid gland.

First she was examined at the Endocrinology Research Center in October 2019. During the CT examination, pronounced exophthalmos of the orbits, thickening of the external rectus oculomotor muscle, tension of the optic nerves were revealed. As a consequence of the ophthalmological examination the diagnosis was established: OU-Graves ophthalmopathy is inactive, of moderate severity. For the purpose of preoperative preparation Diprosan 0.5 ml of peribulbar injections №4 have been performed.

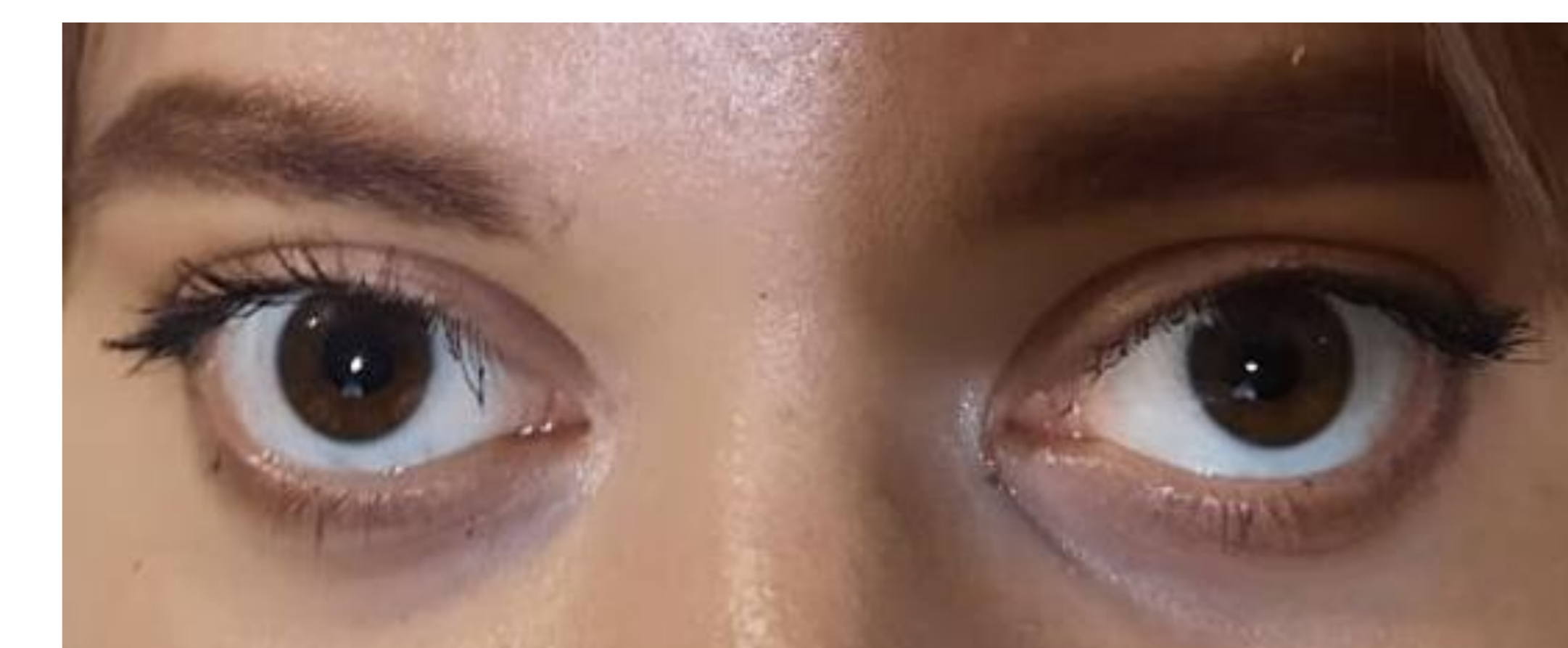Upon re-hospitalization, according to the ultrasound scan of the thyroid gland, the total volume of the thyroid gland was 167.1 cm³. Re-consulted by an ophthalmologist, recommended peribulbar injection of Diprosan for 1 day before the surgery.

11.12.2019 thyroidectomy was performed.

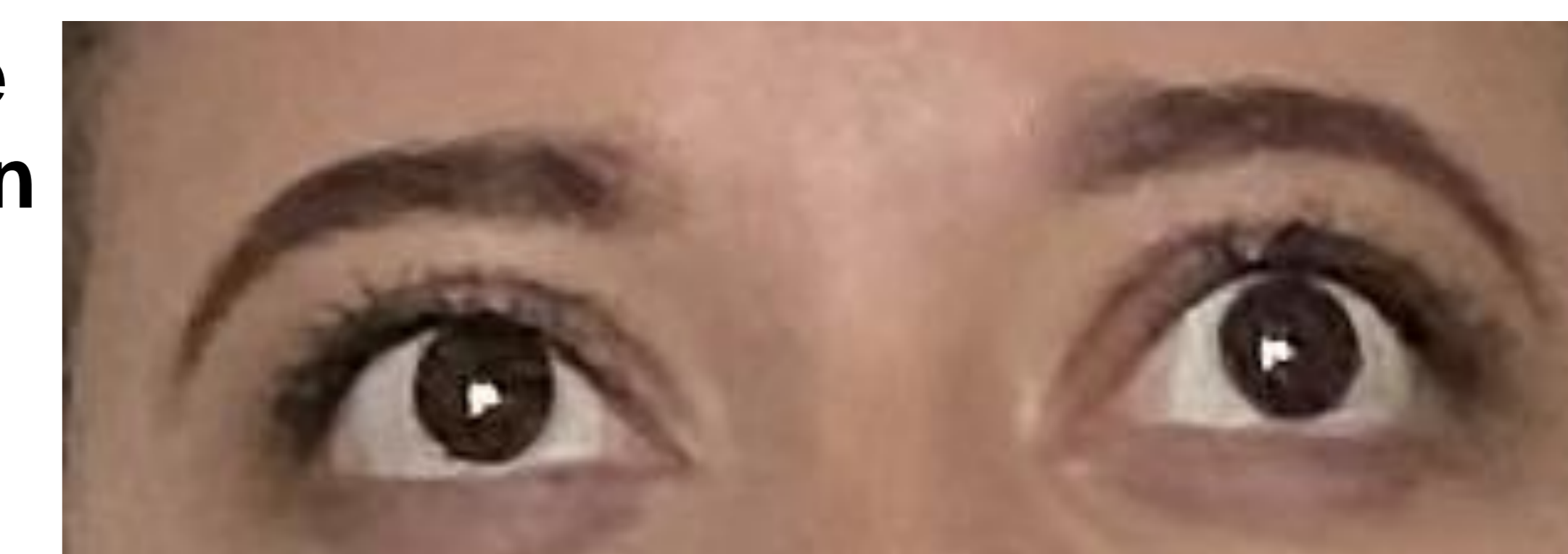In a month after surgical treatment, complaints of photophobia, lacrimation, redness of the sclera, and soreness in the area of the eyeballs are resumed. The patient was examined at the place of residence: according to the results of exophthalmometry negative dynamics was revealed.

In connection with the current situation a collective decision was made on the feasibility of pulse therapy with methylprednisolone in a total dose of 2000 mg.

When performing MR control of orbits (1 month and 9 months after the end of pulse therapy): MR - picture of lipogenic exophthalmos without thickening of the oculomotor muscles. There was a progressive positive dynamics in the form of a decrease in exophthalmos, hydration of retrobulbar fiber. No adverse events were observed.



Pic. 1 Before intravenous introduction of glucocorticoids



Pic. 2 After intravenous introduction of glucocorticoids

CONCLUSIONS

This clinical case of intravenous introduction of large doses of glucocorticoids demonstrated stable positive dynamics of the course of Graves' ophthalmopathy, the absence of adverse events, allows us to use this method in the treatment of the active stage of Graves' ophthalmopathy in children.

CONTACT INFORMATION

ivannikovate@gmail.com

