

# Pituitary stalk interruption syndrome from infancy to adulthood : Clinical, hormonal and radiological assessment according to the initial presentation

Céline Bar<sup>1</sup>, Charline Zadro<sup>2</sup>, Gwenaëlle Diene<sup>1</sup>, Isabelle Oliver<sup>1</sup>, Catherine Pienkowski<sup>1</sup>, Béatrice Jouret<sup>1</sup>, Audrey Cartault<sup>1</sup>, Zeina Ajaltouni<sup>1</sup>, Jean-Pierre Salles<sup>1,3</sup>, Annick Sevely<sup>2</sup>, Maithé Tauber<sup>1,3</sup>, Thomas Edouard<sup>1,3</sup>

<sup>1</sup> Endocrine, Bone Diseases, Genetics, Obesity, and Gynecology Unit, Children's Hospital, University Hospital, Toulouse, France

<sup>2</sup> Neuroradiology Unit, Purpan University Hospital, Toulouse, France

<sup>3</sup> INSERM UMR 1043, Center of Pathophysiology of Toulouse Purpan (CPTP), University of Toulouse Paul Sabatier, Toulouse, France

**Background:** Patients with pituitary stalk interruption syndrome (PSIS) are initially referred for hypoglycemia during the neonatal period or growth retardation during childhood. PSIS is either isolated (non-syndromic) or associated with extra-pituitary malformations (syndromic).

**Objective:** To compare baseline characteristics and long-term evolution in patients with PSIS according to the initial presentation.

**Study design:** Sixty-seven patients with PSIS were included. Data from subgroups were compared: neonates referred for hypoglycemia (n = 10) versus growth retardation patients (n = 47), and syndromic (n = 32) versus non-syndromic patients (n = 35).

**Results:** Neonates displayed a more severe hormonal and radiological phenotype than children referred for growth retardation, with a higher incidence of multiple hormonal deficiencies (100% versus 34%; P = 0.0005, Figure 1) and a nonvisible anterior pituitary lobe (33% versus 2%; P = 0.0017).

Regular follow-up of growth might have allowed earlier diagnosis in the children with growth retardation, as decreased growth velocity and growth retardation were present respectively 3 and 2 years before referral. In addition, we found that 41% of the boys of this subgroup had micropenis and/or cryptorchidism and/or hypoglycemia in the neonatal period. We documented a progressive worsening of endocrine impairment throughout childhood in these patients (Figure 1 and 2).

Presence of extra-pituitary malformations (found in 48%) such as solitary median maxillary central incisor (Figure 4) was not associated with more severe hormonal and radiological characteristics. Growth under GH treatment was similar in the patient groups and did not vary according to the pituitary MRI findings (Figure 3).

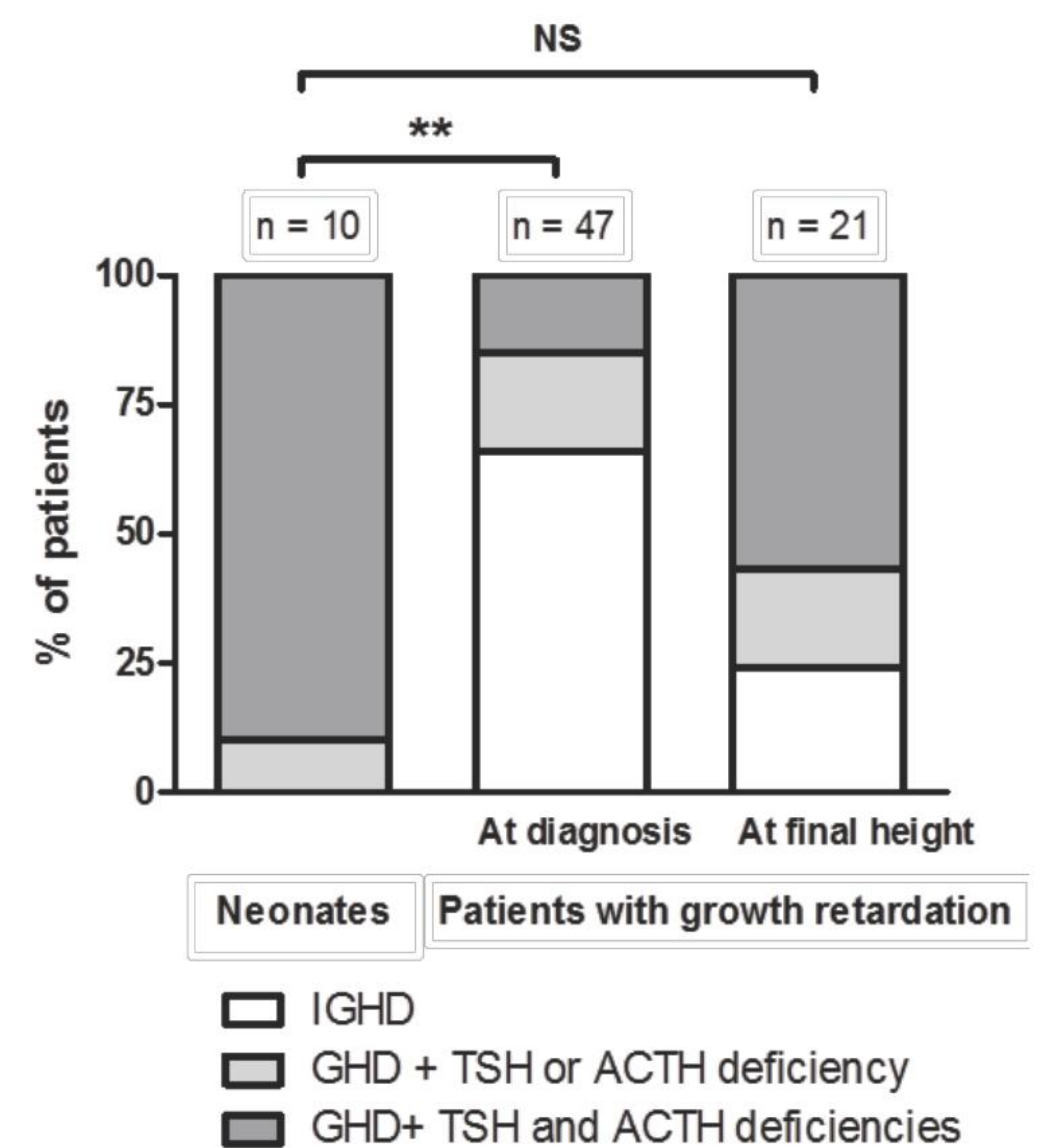


Figure 1

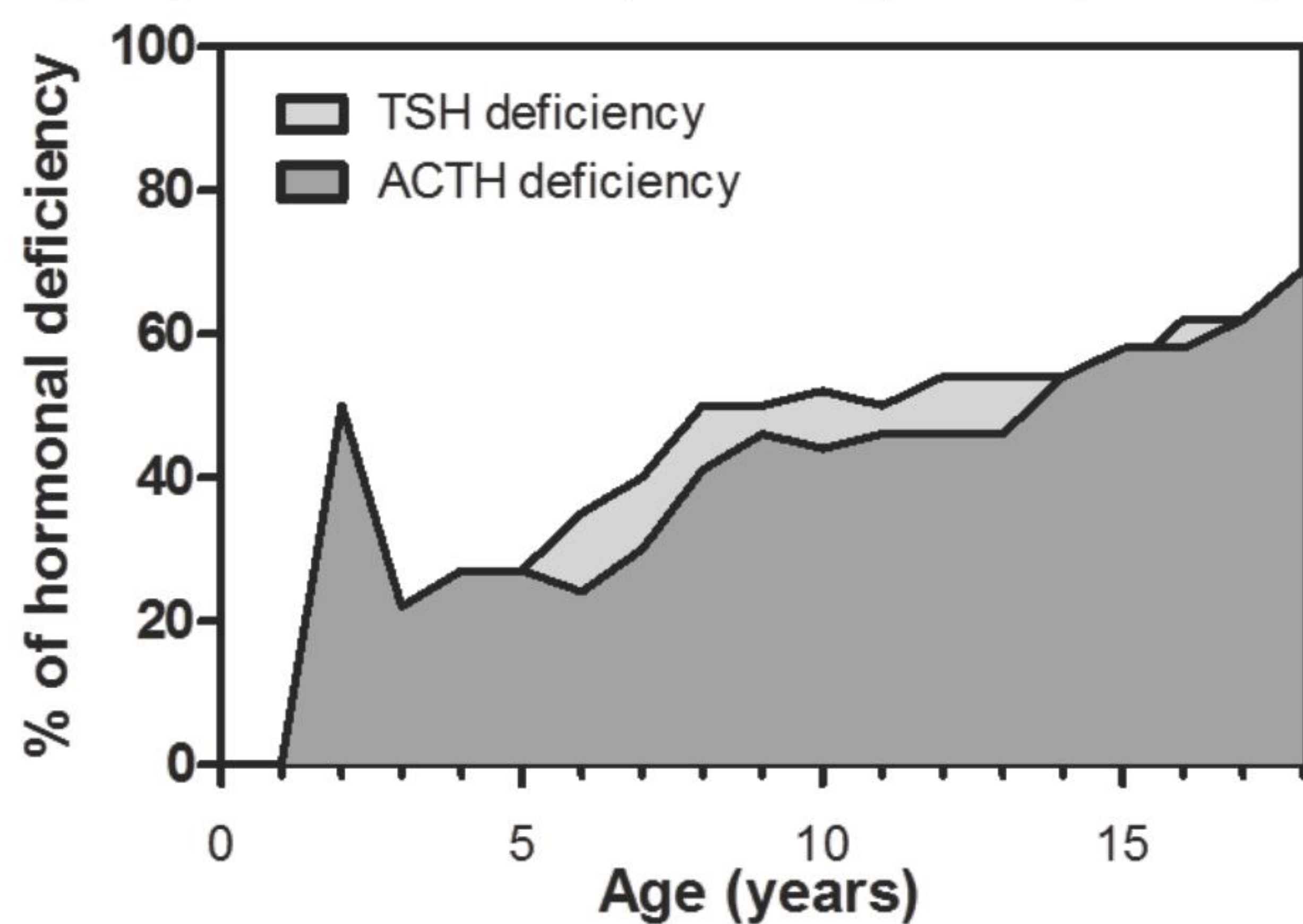


Figure 2

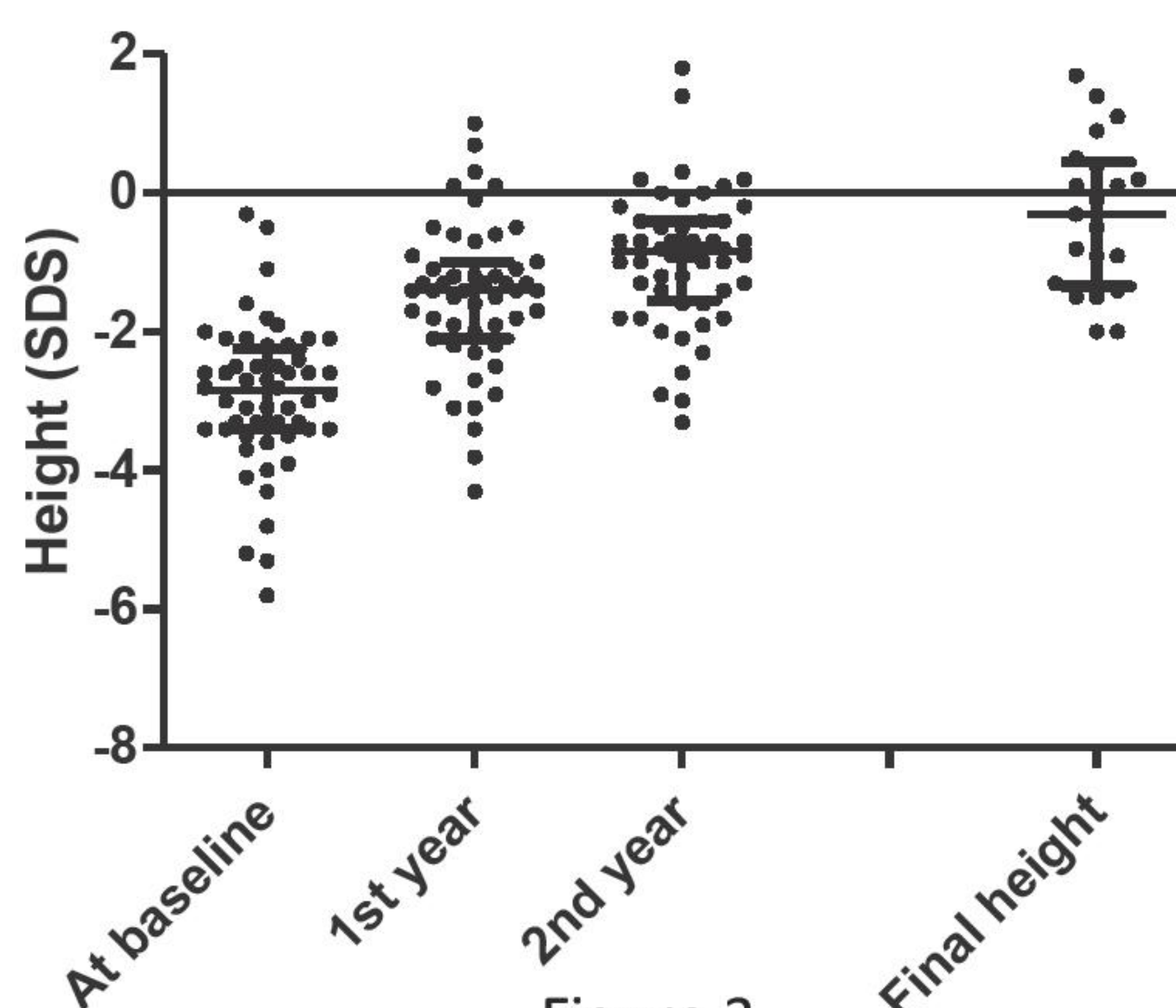


Figure 3

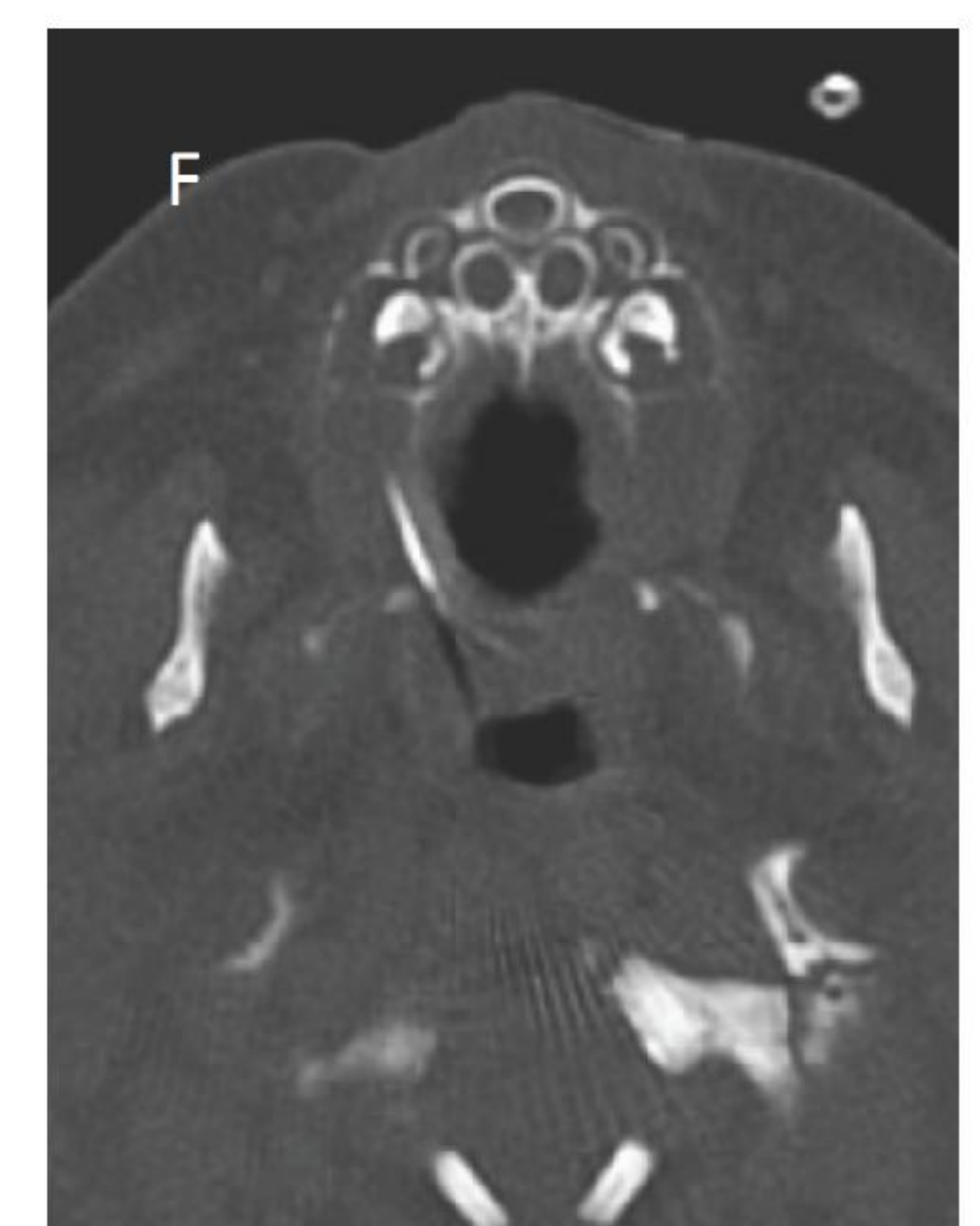

Figure 4

**Conclusions:** PSIS should be considered when micropenis, cryptorchidism and hypoglycemia are present in the neonatal period. PSIS diagnosed in the neonatal period has a particularly severe hormonal and radiological phenotype. Syndromic forms are frequent. The progressive worsening of endocrine impairment throughout childhood justifies periodic follow-up to check for additional hormonal deficiencies.

#### References

- Fujisawa I, et al. Transection of the pituitary stalk: development of an ectopic posterior lobe assessed with MR imaging. *Radiology*. 1987 Nov;165(2):487-9. PubMed PMID: 3659371.
- Reynaud R, Albarel F, Saveanu A, Kaffel N, Castinetti F, Lecomte P, et al. Pituitary stalk interruption syndrome in 83 patients: novel HESX1 mutation and severe hormonal prognosis in malformative forms. *Eur J Endocrinol*. 2011 Apr;164(4):457-65. PubMed PMID: 21270112.
- Pinto G, Netchine I, Sobrier ML, Brunelle F, Souberbielle JC, Brauner R. Pituitary stalk interruption syndrome: a clinical-biological-genetic assessment of its pathogenesis. *J Clin Endocrinol Metab*. 1997 Oct;82(10):3450-4. PubMed PMID: 9329385.
- Tauber M, Chevrel J, Diene G, Moulin P, Jouret B, Oliver I, et al. Long-term evolution of endocrine disorders and effect of GH therapy in 35 patients with pituitary stalk interruption syndrome. *Horm Res*. 2005;64(6):266-73. PubMed PMID: 16260897.